

Spiral CT Image Post-Processing Technology to Guide Hypertensive Cerebral Hemorrhage in Minimally Invasive Removal

Amaren Charu*

Institute of IT & Computer Science, Afghanistan

**corresponding author*

Keywords: Spiral CT, Image Post-Processing Technology, Hypertensive Cerebral Hemorrhage, Minimally Invasive Removal

Abstract: Hypertensive local cerebral hemorrhage is the most common primary local cerebral hemorrhage in my country. The main clinical pathogenic reaction mechanism is acute hypertension and can cause tiny aneurysms in intracranial capillaries and intracranial vitreous vascular lesions. Minimally invasive removal is a surgery widely used in the treatment of hypertensive intracerebral hemorrhage in recent years, and is of great significance for improving the prognosis of patients. The purpose of this article is to study the application of spiral CT image post-processing technology to guide the hypertensive cerebral hemorrhage in minimally invasive removal. Through a study and investigation on spiral CT and hypertensive cerebral hemorrhage, the causes of hypertensive cerebral hemorrhage and the analysis of a series of complications that may occur after surgery. The results of the study showed that the hospital stay of hypertensive cerebral hemorrhage patients with minimally invasive removal surgery was 14 days, the amount of surgical bleeding was 54.82ml, and the operation time was 2.42 hours, while the hospital stay of ordinary cerebral hemorrhage patients with conventional clearance surgery was 24 days. The operation bleeding volume was 412.73ml, and the operation time was 4.23 hours. This shows that the application guidance of spiral CT image post-processing technology and the practical application prospect of hypertensive cerebral hemorrhage in clinical minimally invasive removal technology are very good.

1. Introduction

In recent years, the minimally invasive treatment of cerebral hemorrhage has been widely promoted and applied in China and the country for many years. The superiority of its treatment is obvious compared with the treatment of traditional craniotomy and minimally invasive surgery for

the removal of cerebral hemorrhage tumors. A key issue in the treatment of minimally invasive puncture treatment is how to accurately use puncture to treat hematoma and send the minimally invasive puncture needle directly to the hospital hematoma removal center, so that the treatment of hematoma can be removed as soon as possible. The ordinary cranial CT type image is a two-dimensional computer image, which cannot directly and accurately display the specific shape of the brain hematoma and the position of the three-dimensional tissue in the skull, which directly leads to inaccurate positioning, the puncture needle is easily deviated from the center of the hematoma, and the surgical effect is not ideal.

CT three-dimensional reconstruction technology was developed in 1997, and has been continuously developed for more than ten years. The image obtained by scanning the CT time axis image in the skull is a two-dimensional stereoscopic image of a hematoma. Although surgery can effectively solve many surgical problems in hematoma, it is difficult to achieve an intuitive stereoscopic image effect due to poor stereoscopic [1]. The surgeon often needs to reorganize and organize these two-dimensional images in his two-dimensional mind, and re-establish a three-dimensional correspondence between the three-dimensional shape and size of the hematoma and the surrounding anatomical structure in the new imagination [2]. The three-dimensional reconstruction of spiral CT scan intuitively and accurately displays the spatial location and anatomical relationship of hematoma, and can measure the distance, angle, and volume of three-dimensional space, provide accurate medical anatomical medical basis for surgical patients, and reduce the blindness of surgery [3]. At the same time, the measured hematoma is more accurate than the measurement.

Jabalameili included 108 patients undergoing total knee arthroplasty in two university hospitals. Spiral CT images through the con femur were used to assess the rotation of the distal femur. Four lines are drawn digitally in the view: anatomical and surgical upper icon axis, con posterior axis and Whiteside front and back lines [4]. Ting Yuan study found that doppler changes in hypertension and normal blood pressure groups were evaluated by multi-level modeling methods of single factor and multi-factor adjustment analysis. According to multi-level modeling methods and multivariate correction analysis, doppler vascular impedance make a relatively average assessment. And it was found that hypertension was significantly correlated with the positive correlation of PI, RI and S/D values [5]. Manmadhachary research found that CT images are the main source of manufacturing medical models, and spiral CT scanners can capture larger volumes of tissue in a short time. In his research, he found that the main defects in the CT image acquisition process are beam hardening (BH), image noise and radiation dose. And found that the tube voltage, tube current and pitch are the main parameters of CT image acquisition [6]. In his study, Zhang evaluated the incremental value of single photon emission computed tomography (SPECT)/spiral computed tomography (CT) relative to SPECT to assess ambiguous bone lesions in patients with hepatocellular carcinoma (HCC). In his study, the final diagnosis of each lesion was based on pathological confirmation or follow-up of whole-body scintigraphy, and two or more SPECT/spiral CT examinations were performed [7]. Hongning wanted to determine a Chinese medicine Nao-Xue-Shu oral solution that can protect and improve the secondary brain injury (SBI) of hypertensive cerebral hemorrhage (HCH). He used the Glasgow Outcome Scale (GOS) to assess the incidence of SBI and the classification of prognosis and poor prognosis to evaluate the clinical efficacy, and to determine the level with the changes of IL-6 and TNF- α to study the mechanism of action of traditional Chinese medicine [8].

The main focus of this article is the application of spiral CT image post-processing technology to guide hypertensive cerebral hemorrhage in minimally invasive removal. The innovations of this

article are as follows: First, an overview of spiral CT and hypertensive cerebral hemorrhage and minimally invasive removal surgery. Secondly, the investigation and treatment of minimally invasive surgery to treat hypertensive cerebral hemorrhage. Finally, a case study was conducted on the application of spiral CT image post-processing technology to guide the application of hypertensive cerebral hemorrhage in minimally invasive removal. The important ongoing and clinical discussion of clinical application in clinical minimally invasive tumor removal provides a reasonable reference source of technical evidence for clinical medical imaging research.

2. Overview of Spiral CT and Minimally Invasive Removal of Hypertensive Cerebral Hemorrhage

2.1. Overview of Spiral CT

The spiral CT image scanning technology uses x-ray laser tubes to rotate the image in a continuous direction around the diseased human face in the bed. At the same time, the scan line is automatically reflected from the bed into the bed at a uniform speed, so the scan line is the face of the diseased patient and its appearance are spiral. Unlike the general conventional CT image scanning, the image required for spiral electrogram scanning is the tissue information of the continuous volume level, which is used to scan the volume information of all local tissues within the diagnostic range, so it is also collectively called continuous volume. Organizing the data avoids the huge drawback of local omission of small tissue lesions due to local respiratory tube movements that are easily damaged during CT image scanning under spiral tomography [9]. Digital application of flat-panel laser detectors, due to the use of special laser detectors and new imaging technologies, the scanning imaging speed has been significantly improved, making it possible to use fast, small, thin, high-speed, low-resolution optical scanning technology with large coverage [10].

The basic method of spiral CT can be used to display lesions stereoscopically and simulate the structure of the brain. In some patients, it can also replace invasive examinations. Therefore, the value in the diagnosis and evaluation of cerebral hemorrhage has been gradually affirmed. CT image positioning technology is one of the most important surgical links in minimally invasive vascular puncture. The use of circular spiral arm CT positioning image scanning post-processing positioning technology can not only greatly increase the positioning accuracy of minimally invasive puncture, improve the clearance rate of micro hematoma, but also reduce the side injury during puncture surgery. The large amount of clinical application of spiral rotating CT image technology has further expanded the application range of CT, especially for the image display effect of human organs that are greatly affected by the speed of human motion. One of the main advantages of spiral image scanning is that it is not easy to repeatedly leave various lesion image information, the scanning image speed is fast, and it also has great image flexibility in image signal processing, which can simultaneously obtain various image processing in any direction Level [11]. SCT image post-processing technology has the following advantages over ordinary CT-guided minimally invasive puncture: first, the reconstructed image shows the three-dimensional shape of the hematoma, reflecting the mass effect of the hematoma, allowing the clinician to intuitively understand the severity of the disease. Second point: 3D determines the best puncture point to ensure that the puncture needle enters the hematoma cavity with the best approach. Third point: after successful puncture, determine the position of the hematoma and puncture needle, adjust the depth of the puncture needle and the direction of the side hole, the maximum amount clear the hematoma; the fourth point, accurate positioning, significantly reduces the possibility of accidentally damaging normal brain tissue, and the probability of secondary bleeding is

significantly reduced [12].

MPR images are images of coronal, sagittal, oblique, and entire curved surfaces from a volumetric image database of spiral and CT values. The disadvantage is that improper selection of MPR plane can also cause artifacts and omissions. Therefore, it must be carefully compared with the cross-sectional image. Three-dimensional reconstruction can be divided into linear reconstruction, surface reconstruction (SSD) and volume reconstruction (VRT) [13]. VRT is to give all the crystal elements in the data according to different brightness percentages and different color transparency and gray levels. The contrast of the image and the relative density of each pixel can be adjusted in real time and interactively by manipulating the trapezoidal conversion function [14]. In addition, on the basis of MIP, a new technology—Sliding Thin Layer Technology (STS) has been developed [15]. STS contains a series of sliding layers composed of several consecutive 1mm thin layers. Each pixel in each 1mm thin layer represents the voxel with the largest (or smallest) density in a particular sliding layer. The advantage of STS technology is that it can display a relatively long range of blood vessels and airways on a single-layer image, thus providing a more ideal way to observe its natural branches [16].

2.2. Overview of Minimally Invasive Removal of Hypertensive Cerebral Hemorrhage

Hypertensive cerebral hemorrhage is a common clinical disease and one of the most frequent diseases. At present, a variety of traditional minimally invasive abdominal cardiovascular valvular artery removal surgery has been successfully clinically achieved a certain amount of surgical treatment. The application of spiral CT image three-dimensional reconstruction technology has the following advantages over ordinary CT in guiding minimally invasive puncture: in the measurement of hematoma, the amount of hematoma measured by the three-dimensional image reconstruction application software on the workstation is more accurate [17]. The detection of the location of blood tumors is unthinkable by the reasonable integration of the two-dimensional imaging information system of the human axis, and the detection results produced by this will obviously not have large errors. Minimally invasive hematoma surgery evaluation indication verification assessment is based on the minimally invasive image anatomy method for surgical evaluation [18]. The reconstructed image is intuitive and accurate, which allows clinicians to understand the severity of the disease more clearly and guide the determination of surgical indications accurately [19]. Use three-dimensional CT image stereo positioning to determine the best puncture point and ensure that the puncture needle enters the hematoma cavity with the best approach; make the drainage tube accurately reach the center of the hematoma, and design the path of the drainage tube according to the three-dimensional shape and volume of the hematoma. Pass the drainage tube through the longest axis of the hematoma [20].

Minimally invasive hematoma removal treatment uses the treatment of intracranial positive pressure continuous crushing and washing cells to liquefy for drainage, and the positive pressure crushing and washing liquefaction of intracranial local hematoma cells to quickly and accurately clear intracranial hematoma, relieve intracranial hematoma pressure, and treat acute New generation technology for cerebral hemorrhage [21]. During the whole process of treatment, the patient can only receive a local injury of craniotomy, which can effectively keep the intracranial blood pressure stable, so the treatment has a good prognosis, which can be used to greatly reduce the mortality rate and improve the overall quality of life of the patient [22]. Hypertensive patients' severe and rapid rise in local blood pressure due to excessive emotional excitement will directly lead to severe rupture of the local cerebral vascular edema that has occurred, resulting in a crisis of cerebral hernia,

such as lateral expansion of the local hematoma or gradual pupil dilation, and the blood pressure rises sharply high. Subsequent severe central heart failure can endanger human life and safety [23].

The minimally invasive removal technique for hypertensive cerebral hemorrhage is an effective method for the treatment of intracranial hematoma with hypertension. The pulverize and biochemical enzyme analysis technology replace the traditional craniotomy to achieve the purpose of removing intracranial hematoma [24]. Minimally invasive surgery has completely broken through the technical limitations on the age and physical condition of patients with cerebral hemorrhage. It has been widely applied and popularized in the clinical and treatment of minimally invasive surgery for the treatment of hypertension and acute cerebral hemorrhage. Dade improves the clinical treatment efficiency and quality of acute cerebral hemorrhage [25]. One of the main methods and purposes of the research on the minimally invasive technology of this research topic is to conduct clinical investigations, and the post-processing analysis technology of spiral CT images is to guide the importance and application prospects of hypertensive acute cerebral hemorrhage in the treatment of clinical minimally invasive removal technology research.

At present, the commonly used minimally invasive treatment methods are divided into two kinds of treatment methods: neurology and craniocerebral surgery. However, it is generally believed that although surgery is effective in removing acute hematoma in the brain of patients in emergency. However, due to the relatively high risk of conventional minimally invasive surgical treatment and the serious damage to normal brain nerve tissue, with the rapid and in-depth development and promotion of the current minimally invasive first aid technology.

3. Main Research Content of the Experiment

3.1. Research Purposes

In this paper, the application of spiral CT image post-processing technology to guide the application of hypertensive cerebral hemorrhage in minimally invasive removal has been studied and analyzed. Obvious glassy degeneration, and it is easy to seriously damage normal brain nerve tissue. With the rapid promotion of development and application of intracranial minimally invasive treatment technology, spiral CT minimally invasive intracranial local hematoma removal is currently used to treat hypertensive acute brain in China. The field of hemorrhage treatment has successfully achieved great results. In order to understand the importance and application of spiral CT intracranial minimally invasive image post-processing technology for the treatment of hypertensive acute cerebral hemorrhage in the treatment of intracranial minimally invasive removal, it provides professional medical personnel with reasonable treatment based on imaging to provide a reference and scientific basis for a reliable treatment plan, the study in this paper deeply analyzes the importance of post-processing techniques of spiral CT intracranial minimally invasive images for the treatment of hypertensive acute cerebral hemorrhage in the treatment of intracranial minimally invasive removal and applications.

This article will analyze and analyze the clinical situation of 86 cases of typical hypertensive acute advanced cerebral hemorrhage encephalopathy patients who have undergone long-term clinical examination and diagnosis and treatment in clinical clinics of some large encephalopathy hospitals as the key objects of the main examination research, statistics and analysis of patients with hypertensive cerebral hemorrhage. Through the guidance of spiral CT image post-processing technology and then minimally invasive removal, the application of spiral CT image post-processing technology to guide hypertensive cerebral hemorrhage in minimally invasive removal was studied. Therefore, the main aims of the research in this article are: (1). To understand

the situation of hospitalized patients with hypertensive cerebral hemorrhage. (2). To study the recovery effect of hospitalized patients with hypertensive cerebral hemorrhage before and after treatment. (3) To compare patients with normal cerebral hemorrhage and hypertensive brain hemorrhagic patients use spiral CT image post-processing technology to guide the different effects after treatment, and provide a reference and basis for guiding spiral CT image post-processing technology.

3.2. Main Research Object

A total of 40 patients with minimally invasive cerebral hemorrhage removal who were treated with routine hypertension and minimally invasive cerebral hemorrhage removal in the laboratory of a hospital from October 2013 to July 2015 were selected as the control group. The hospital used 46 patients with hypertension who were treated with high blood pressure routine surgery and minimally invasive cerebral hemorrhage removal laboratory as the observation group. Among the 40 hypertensive patients in the control group, there were 25 males and 15 females, aged 37-79 years, with an average age of (57.5 ± 4.4) years old, with a bleeding volume of 15-79 ml, with an average of (32.6 ± 1.8) ml. Among the 46 hypertensive patients in the observation group, 29 were male and 17 were female. They were 36 to 80 years old, with an average age of (57.7 ± 4.3) years old, and had a bleeding volume of 15 to 80 ml, with an average of (32.8 ± 1.7) ml.

3.3. Research Methods

In this treatment study, some effective treatments and nursing methods were used.

Preoperative localization: All cases were treated with lowering blood pressure, dehydration, prevention of complications, etc. At the same time, according to the initial CT film showing the location of the hematoma on the scalp, the metal marker a was placed, and spiral CT scan was performed before puncture. The three-dimensional structure of the hematoma was reconstructed using surface covering scanning imaging and surface fluoroscopic imaging technology respectively, and the image was retained as a basis.

In the control group, the small bone window craniotomy hematoma was first removed, and the hematoma was removed first, using CT orientation, and the position suitable for incision was selected according to the patient's bleeding position. The location of the hematoma was checked with a cerebral puncture needle. Afterwards, the narrow brain pressure plate enters the hematoma cavity along the puncture needle channel, and the wounds are sequentially reset and sterile bandaged. Corresponding antibiotic or urokinase injection treatment should be done after the operation.

Suction hemorrhage: After successful first puncture, suction hemorrhage followed by a spiral CT first puncture needle local scan, slow suction hemorrhage. The first bleeding suction volume cannot exceed the initial suction hematoma suction 60% of the total number of aspirations, using image post-processing technology to display the three-dimensional image of the residual hematoma and the position of the puncture needle, adjust the depth of the puncture needle, maintain the needle tip at the center of the main body of the hematoma, and adjust the side hole of the puncture needle so that it points. In the direction of the main body of the hematoma, continue to suck the residual hematoma.

Observation group patients were treated with minimally invasive intracranial hematoma comminuted and removed intracranial hematoma. Before the operation, CT scan of the blunt head was performed to determine the location of the bleeding in the needle body. Psychological

preparation, lay sterile towels and hole towels in the needle body after disinfection, check whether there are abnormalities such as vascular pulsation in the lower half of the needle body puncture point, try to avoid it when performing a single puncture at the puncture point. Infiltrate the anesthesia locally at the puncture site, remove the cap on the tail of the needle body, install a needle-shaped intracranial hematoma crusher to wash the hematoma cavity of the needle body with the needle-shaped hematoma crushing liquid, inject the hematoma liquefaction agent to close the hematoma fluid in the two side tubes spill the channel and apply a sterilized dressing for dressing. After operation, hematoma fluid was treated with antibiotics or urokinase injection. The following is a comparison of the evaluation results of the BARTHAL index before and after treatment of patients with hypertensive cerebral hemorrhage in the observation group, as shown in Table 1.

Table 1. Comparison of evaluation results of BARTHAL index in patients with hypertensive cerebral hemorrhage before and after treatment

Time	75~100 point	50~70 point	0~45 point
Before treatment	4	19	17
Two weeks after treatment	18	12	10

After the patient is admitted to the hospital, the neurosurgeon decides whether the patient is fully suitable for surgery. Nurses should first carefully observe the patient's physiological consciousness, pupils, vitality and other signs during the consultation, especially the patient's blood pressure. Correctly assess the criticality of a patient's preoperative condition, and carefully make inspection records. Establish a venous blood pressure monitoring channel, dissolve 50ml of sodium nitroprusside hydrochloride in 50ml of 50% glucose sodium nitroprusside solution, put it into a trace infusion pump, adjust the infusion speed, and monitor the venous blood pressure.

Closely observe the patient's vital signs and other physical activity changes. Accurately record the in and out volume of 24h. It is recommended that the patient stay in a supine position, and those with poor respiratory tracheal function should close or cut the respiratory trachea in time, strictly in accordance with the routine requirements of tracheotomy surgery. Pay attention to observe the phenomenon of bleeding and infection in the skull at any time. Strictly aseptic rinsing during rinsing must be performed gently and steadily. During the rinsing process, keep the balance of in and out volume. If more than in and out, it may cause high intracranial pressure.

4. Study on Application of Spiral CT Image Post-Processing Technology to Guide Hypertensive Cerebral Hemorrhage in Minimally Invasive Removal

4.1. Investigation and Analysis of the Application of Spiral CT Image Post-Processing Technology to Guide Hypertensive Cerebral Hemorrhage in Minimally Invasive Removal

Patients with normal cerebral hemorrhage are treated with conventional craniotomy hematoma removal, usually reaching a depth of about 5 cm to reach the hematoma cavity, which is conducive to completely separating the lateral fissure through the anterior middle guide lobe to enter the cortex to remove the hematoma. The injury is mild, but the patient should try to avoid damage to the vascular cortex of the lateral fissure via the guide lobe. After clearing the hematoma, observe whether there is active bleeding. If there is bleeding, acute electrocoagulation should be used to stop

bleeding, but do not use electrocoagulation blindly. After the operation, the skull was closed and sutured. The comparison of specific operations is shown in Table 2.

Table 2. Comparison of NIHSS scores before and after treatment in 2 groups

Group	Before treatment	After treatment
Control group	24.08	12.26
Observation group	23.86	4.29
t value	0.287	18.458
P value	0.774	0

In the treatment of hypertensive acute cerebral hemorrhage congenital heart disease patients with minimally invasive cerebrovascular removal surgery, the average score of the NIHSS control group before treatment was 23.86, and the score after treatment was 4.29, the score decreased significantly. For patients with common cerebral hemorrhage, the NIHSS score was 24.08 before treatment with conventional removal surgery and 12.26 after treatment.

For patients with hypertensive cerebral hemorrhage, minimally invasive examination and removal of intracranial hematoma are performed, and the location of intracranial hematoma and the amount of bleeding in the operating room are fully and accurately grasped by using CT or other medical examination techniques. To confirm, after using the puncture needle to pass through the skull of the patient, remove the electric drill and the drill bit, insert the needle core in the cavity and slowly push it into the center of the needle-shaped hematoma crusher, pull out the needle core, and old blood can be seen. Flowing out of the cavity, the urokinase syringe is connected to slowly aspirate the center of the hematoma. The statistics about the operation duration, the amount of bleeding in the operating room and the number of days of operation during the hospitalization of the two groups are shown in Figure 1.

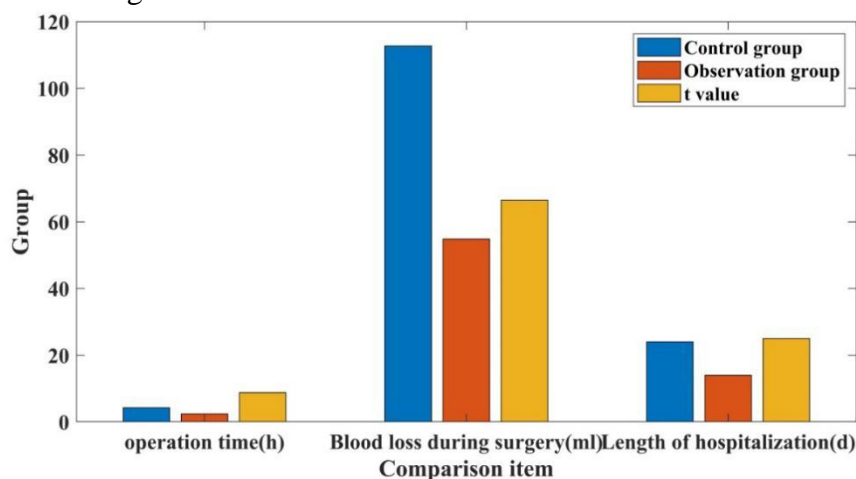


Figure 1. Schematic diagram of the comparison of the operation-related conditions of the 2 groups of patients

As can be seen from the data in Figure 1, the operation duration of the observation group and the hospitalization duration of the observation group were significantly shorter than that of the observation control group, and the bleeding volume of patients during the operation was significantly less than that of the observation control group, and the differences were of clinical and statistical significance ($p < 0.5$). The results of the experiment using minimally invasive surgery to

remove cerebral hemorrhage in the observation group. The duration of surgery and hospitalization of hypertensive patients with acute cerebral hemorrhage was 14 days. The duration of bleeding in the surgical patients was 54.82 ml. The patient was hospitalized for 24 days with routine removal surgery, the bleeding volume was 412.73 ml, and the surgery time was 4.23 hours.

According to the evaluation results of NIHSS treatment score, the effect of patients receiving treatment is determined. The cure rate is the reduction rate of the patient's NIHSS score after treatment from 91% to 100%; the significant effect is the reduction rate of the patient's NIHSS treatment score after treatment from 46% to 90%; the effective is the reduction rate of the patient's NIHSS score after treatment 18~45%; invalid is that the NIHSS treatment score of patients after treatment has not changed or even worsened. The total effective rate of treatment = (cure + marked effect + effective) / total number of treatment cases * 100%. Evaluation results the 40 cases of hypertensive patients with acute cerebral hemorrhage in the control group had no obvious effect on the treatment of postoperative hypertension with minimally invasive removal therapy, as shown in Figure 2.

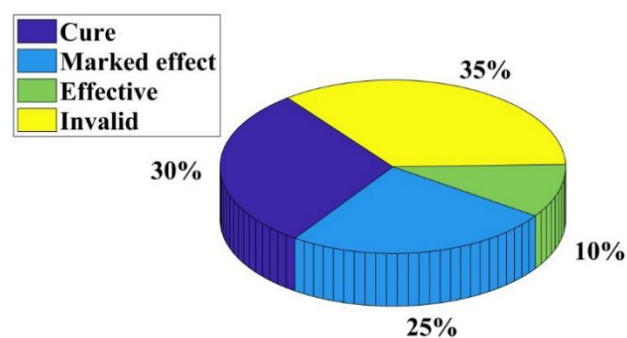


Figure 2. Schematic diagram of the clinical efficacy of the control group

As can be seen from the data in Figure 2, after 40 patients with hypertensive cerebral hemorrhage in the control group were treated with minimally invasive removal surgery, 14 patients were ineffective, accounting for 35%, and 10 were significantly effective. There were 4 cases with effective treatment, accounting for the proportion, and 12 cases were cured, accounting for 30%.

4.2. Discussion on the Application of Spiral CT Image Post-Processing Technology to Guide the Application of Hypertensive Cerebral Hemorrhage in Minimally Invasive Removal

The degree of clinical neurological deficits in stroke patients was evaluated according to the "scoring criteria for clinical neurological deficits in stroke patients" developed and adopted. This standard includes strokes the patient's 8 aspects were evaluated in most aspects. The total score of the 8 aspects was 0~45, of which 0~15 were light, 16-30 were medium, and 31~45 were heavy. The development of patients' normal viability was evaluated by the method of BARTHAL index. This scoring standard mainly includes assessment of 10 aspects of stroke patients' dependence. The total score of 10 aspects ranges from 0 to 100 points, of which 0 to 45 divided into complete dependence and severe complete dependence, 50~70 divided into moderate complete dependence, 75~100 divided into mild complete dependence and independence. The comparison of the degree of neurological deficit before and after treatment in patients with hypertensive cerebral hemorrhage, as shown in Figure 3.

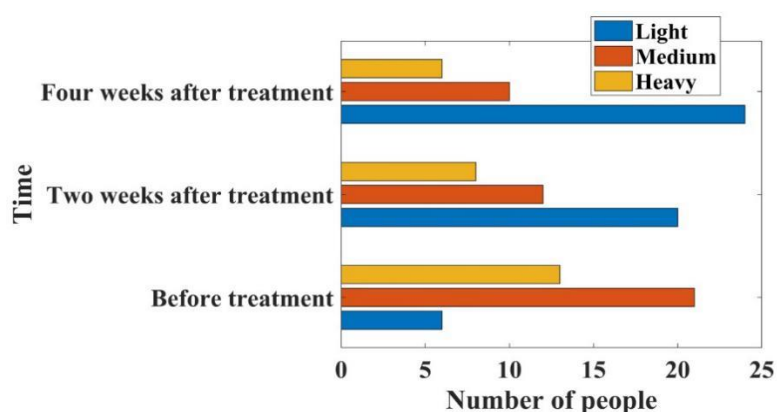


Figure 3. Schematic diagram of the comparison of neurological deficits in patients with hypertensive cerebral hemorrhage before and after treatment

As can be seen from the data in Figure 3, patients with hypertensive intracerebral hemorrhage had 6 cases of mild neurological deficit before treatment, accounting for 15% of the total, 21 cases of medium type, accounting for 52.5%, and 13 cases of heavy for example, it accounts for 32.5%. In the 2 weeks after treatment, patients with hypertensive intracerebral hemorrhage accounted for 20 cases with mild neurological function, which is the general number. Medium and heavy cases accounted for 12 and 8 cases, respectively, accounting for 30% and 20%. In the 4 weeks after treatment, patients with hypertensive cerebral hemorrhage accounted for 24% of the patients with mild neurological function, more than half of the total, accounting for up to 60%. There were 10 cases of medium and 6 severe cases.

Patients with high blood pressure leading to cerebral hemorrhage may often have a series of complications due to high fever after surgery. Most patients with cerebral hemorrhage will be accompanied by high fever after operation. If it exceeds 38°C, effective physical cooling measures should be taken in time. Patients with high fever coma may continue to apply ice on the patients' large intestine such as groin, axilla, neck after operation. In the process of physical cooling after surgery, the patient's body temperature is measured every 30 minutes, and after the operation, pay attention to carefully observe the skin color and the effect of physical cooling. If the body temperature is above 39°C after the operation, the sleeping mixture can be applied after the operation, and the physical ice compress after the operation can be used to cool down. For example, warm water, alcohol rubbing bath after the operation or ice cap and ice blanket after the operation can be used to make the operation postoperative. Body temperature gradually dropped to normal. Some patients with cerebral hemorrhage are often accompanied by constipation or stubborn diarrhea after surgery. They exert force during bowel movements, and abdominal pressure increases significantly, which may result in marked increase in intracranial pressure and easy bleeding. Therefore, patients should be fed with green leafy vegetables and fresh fruits and vegetables rich in plant cellulose. If necessary, patients can be given azalea or sienna tea, and nourishing yin and intestine should be used to help patients maintain. Its stool is smooth. In addition, a small number of patients with cerebral hemorrhage may have constipation or stubborn diarrhea after surgery, which is mainly related to patients' overeating or imbalance of intestinal flora, etc., and it must be effectively prevented and treated in time. Specific hypertensive cerebral hemorrhage patients may cause complications after surgery, as shown in Figure 4.

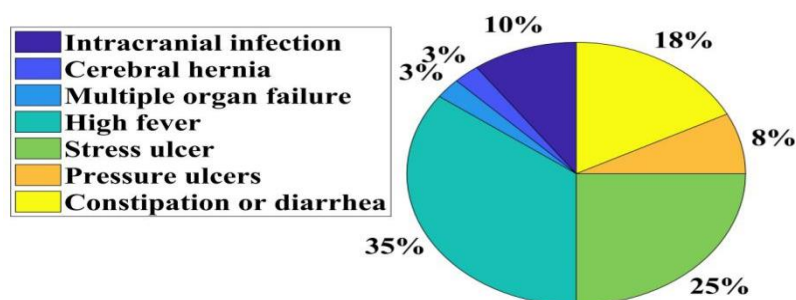


Figure 4. Proportion diagram of various complications after surgery in patients with hypertensive cerebral hemorrhage

It can be seen from Figure 4 that hyperthermia is the most common complication of acute hypertension and cerebral hemorrhage in patients with coronary heart disease after surgery. There are 14 cases in total, which account for up to 35%. Among the complications, cerebral hernia and multiple organ failure accounted for the smallest, only 3%, intracranial infection and stress ulcer were 4 cases and 14 cases, accounting for 10% and 25%, pressure ulcer and constipation, diarrhea respectively. There are 3 cases and 7 cases, accounting for 8% and 18%.

5. Conclusion

(1) Hypertensive early cerebral hemorrhage is a clinically common multiple cardiovascular and cerebrovascular disease. Patients with hypertensive early cerebral hemorrhage in China account for about 10% to 20% of all hypertensive stroke patients. The mortality rate of early cerebral hemorrhage can be as high as 49.1% on average, and the incidence rate has been rapidly increasing year by year in recent years, seriously threatening the personal life and health of the general public with hypertension. In recent years, with the rapid development of bone flap spiral craniotomy and CT image post-processing technology, the diagnosis and treatment of early hypertensive cerebral hemorrhage has gradually changed from the previous traditional bone flap spiral craniotomy and small bone window craniotomy for minimally invasive removal.

(2) Hyperthermia is the most prone complication of hypertensive cerebral hemorrhage patients after surgery, with 14 cases in total, accounting for up to 35%. Among the complications, cerebral hernia and multiple organ failure accounted for the smallest, only 3%, intracranial infection and stress ulcer were 4 cases and 14 cases, respectively, accounting for 10% and 25%, pressure ulcer and constipation, diarrhea respectively. There are 3 cases and 7 cases, accounting for 8% and 18%, respectively. The treatment of minimally invasive diagnosis and removal has obvious characteristics such as small trauma and fast recovery. It has developed into an important method for clinical diagnosis and treatment of hypertension and prevention of early cerebral hemorrhage in hypertension.

(3) Before treatment, 21 patients with hypertensive intracerebral hemorrhage had moderate neurological deficits, accounting for up to 52.5%, and 13 patients with severe impairment, accounting for 32.5%. In the 2 weeks after treatment, patients with hypertensive intracerebral hemorrhage accounted for 20 cases with mild neurological function, which is the general number. Medium and heavy cases accounted for 12 and 8 cases, respectively, accounting for 30% and 20%. In the 4 weeks after treatment, patients with hypertensive cerebral hemorrhage accounted for 24%

of the patients with mild neurological function, more than half of the total, accounting for up to 60%. There were 10 cases of medium and 6 severe cases.

Funding

This article is not supported by any foundation.

Data Availability

Data sharing is not applicable to this article as no new data were created or analysed in this study.

Conflict of Interest

The author states that this article has no conflict of interest.

References

- [1] Blois S M, Dechend R, Barrientos G, et al. A potential pathophysiological role for galectins and the renin–angiotensin system in preeclampsia. *Cellular & Molecular Life Sciences*, 2015, 72(1):39-50. DOI:10.1007/s00018-014-1713-1
- [2] Jenkins, D. Pulmonary endarterectomy: the potentially curative treatment for patients with chronic thromboembolic pulmonary hypertension. *European Respiratory Review*, 2015, 24(136):263-271. DOI:10.1183/16000617.00000815
- [3] Gelber S E, Brent E, Redecha P, et al. Prevention of Defective Placentation and Pregnancy Loss by Blocking Innate Immune Pathways in a Syngeneic Model of Placental Insufficiency. *Journal of Immunology*, 2015, 195(3):1129-1138. DOI:10.4049/jimmunol.1402220
- [4] Jabalameli, Mahmoud, Moradi, Amin, Bagherifard, Abolfazl. Evaluation of Distal Femoral Rotational Alignment with Spiral CT Scan before Total Knee Arthroplasty (A Study in Iranian Population). *arch bone jt surg*, 2016, 4(2):122-127. DOI:10.1017/S1041610297004006
- [5] Yuan T, Zhang T, Li C, et al. A New Perspective to Evaluate Doppler Vascular Impedance in Hypertensive Disorders Complicating Pregnancy: Multilevel Modeling Established in a Case Control Study. *Open Journal of Obstetrics and Gynecology*, 2015, 05(6):350-359. DOI:10.4236/ojog.2015.56051
- [6] Manmadhachary A, Ravi Kumar Y, Krishnanand L. Effect of CT acquisition parameters of spiral CT on image quality and radiation dose. *Measurement*, 2017, 103(2):18-26. DOI:10.1016/j.measurement.2017.02.020
- [7] Zhang Y, Shi H, Li B, et al. The added value of SPECT/spiral CT in patients with equivocal bony metastasis from hepatocellular carcinoma. *Nuklearmedizin*, 2015, 54(06):255-261. DOI:10.3413/Nukmed-0730-15-03
- [8] Jiang H, Qin Y, Liu T, et al. Nao-Xue-Shu Oral Liquid Protects and Improves Secondary Brain Insults of Hypertensive Cerebral Hemorrhage. *Evidence Based Complementary & Alternative Medicine*, 2016, 2016(4):1-6. DOI:10.1155/2016/9121843
- [9] Evangelista A, Czerny M, Nienaber C, et al. Interdisciplinary expert consensus on management of type B intramural haematoma and penetrating aortic ulcer. *European Journal of Cardio Thoracic Surgery*, 47(2):209-217. DOI:10.1093/ejcts/ezu386
- [10] Llorba E, Crispi F, Verlohren S. Update on the Pathophysiological Implications and Clinical

- Role of Angiogenic Factors in Pregnancy. Fetal Diagnosis and Therapy*, 2015, 37(2):81-92. DOI:10.1159/000368605
- [11] Bai C F, Wang Y, Luo Q, et al. Diagnostic value of 320 rows spiral CT for multiple rib fractures. *Academic Journal of Second Military Medical University*, 2015, 36(8):927-929. DOI:10.3724/SP.J.1008.2015.00927
- [12] LI Bai-tao, Chen Chun-Lin, Chen Li-xing. *The Clinical Study of Soft Channel Minimally Invasive Technology Operation in Treating Hypertensive Cerebral Hemorrhage. medical innovation of china*, 2015, 25(5):488-492.
- [13] Bissolati M, Orsenigo E, Staudacher C. Role of minimally invasive surgery in the treatment of diverticular disease: an evidence-based analysis. *Updates in Surgery*, 2015, 67(4):353-365. DOI:10.1007/s13304-015-0329-9
- [14] Marescaux J, Diana M. Next step in minimally invasive surgery: hybrid image-guided surgery. *Journal of Pediatric Surgery*, 2015, 50(1):30-36. DOI:10.1016/j.jpedsurg.2014.10.022
- [15] Ranzani T, Cianchetti M, Gerboni G, et al. A Soft Modular Manipulator for Minimally Invasive Surgery: Design and Characterization of a Single Module. *Robotics, IEEE Transactions on*, 2016, 32(1):187-200.
- [16] Park P, Wang M Y, Lafage V, et al. Comparison of two minimally invasive surgery strategies to treat adult spinal deformity. *Journal of Neurosurgery Spine*, 2015, 22(4):374-380.
- [17] Schols R M, Connell N J, Stassen L P S. Near-Infrared Fluorescence Imaging for Real-Time Intraoperative Anatomical Guidance in Minimally Invasive Surgery: A Systematic Review of the Literature. *World Journal of Surgery*, 2015, 39(5):1069-1079. DOI:10.1007/s00268-014-2911-6
- [18] Shi C, Luo X, Qi P, et al. Shape Sensing Techniques for Continuum Robots in Minimally Invasive Surgery: A Survey. *Biomedical Engineering IEEE Transactions on*, 2017, 64(8):1665-1678. DOI:10.1109/TBME.2016.2622361
- [19] Hanley D F, Thompson R E, Muschelli J, et al. Safety and efficacy of minimally invasive surgery plus alteplase in intracerebral haemorrhage evacuation (MISTIE): a randomised, controlled, open-label, phase 2 trial. *lancet neurology*, 2016, 15(12):1228-1237.
- [20] Dec M, Andruszkiewicz P. Anaesthesia for minimally invasive surgery. *Videosurgery & Other Miniinvasive Techniques*, 2015, 10(4):509-514.
- [21] Scalici J, Laughlin B B, Finan M A, et al. The trend towards minimally invasive surgery (MIS) for endometrial cancer: An ACS-NSQIP evaluation of surgical outcomes. *Gynecologic Oncology*, 2015, 136(3):512-515. DOI:10.1016/j.ygyno.2014.11.014
- [22] Gerboni G, Ranzani T, Diodato A, et al. Modular soft mechatronic manipulator for minimally invasive surgery (MIS): overall architecture and development of a fully integrated soft module. *Meccanica*, 2015, 50(11):2865-2878. DOI:10.1007/s11012-015-0267-0
- [23] Henk V D P, Brinkman W, Van Cleynenbreugel B, et al. Training in minimally invasive surgery in urology: European Association of Urology/International Consultation of Urological Diseases consultation. *BJU International*, 2016, 117(3):515-530. DOI:10.1111/bju.13320
- [24] Liu X C, Jing L Y, Yang M F, et al. Enhanced Neuroprotection of Minimally Invasive Surgery Joint Local Cooling Lavage against ICH-induced Inflammation Injury and Apoptosis in Rats. *Cellular & Molecular Neurobiology*, 2016, 36(5):647-655. DOI:10.1007/s10571-015-0245-z
- [25] Ou K L, Weng C C, Sugiatno E, et al. Effect of nanostructured thin film on minimally invasive surgery devices applications: characterization, cell cytotoxicity evaluation and an animal study in rat. *Surgical Endoscopy*, 2015, 30(7):3035-3049. DOI:10.1007/s00464-015-4596-9