

A Case of Recurrent Oral Ulcer Caused by Oral Clopidogrel Tablets Treated With Traditional Chinese Medicine

Rui Lan^{1, a} and Zhixiang Zhang^{2, b*}

¹*Shaanxi University of Chinese Medicine, Xianyang 712046, Shaanxi, China*

²*Affiliated Hospital of Shaanxi University of Chinese Medicine, Xianyang 712046, China*

^a*1849739208@qq.com*, ^b*33321006@163.com*

^{*}*corresponding Author*

Keywords: Clopidogrel, Recurrent Oral Ulcer, Traditional Chinese Medicine

Abstract: A case of recurrent oral ulcer caused by oral clopidogrel tablets was treated with traditional Chinese medicine. The characteristics of traditional Chinese medicine treatment were analyzed and the clinical experience was summarized. Through comparison the advantages of traditional Chinese and western medicine in the treatment of recurrent oral ulcer caused by clopidogrel tablets. Encourage more medical personnel USES the thinking of traditional Chinese medicine overall sits, syndrome differentiation and treatment, rational use of traditional Chinese medicine to alleviate pain patients.

1. Case Data

A 76-year-old male patient was admitted to the First Affiliated Hospital of Xi 'an Jiaotong University in November 2016 because of intermittent chest tightness, shortness of breath, chest pain, pain radiating to the left shoulder, left upper limb and neck, accompanied by sweat, nausea and fatigue. Electrocardiogram showed sinus rhythm (57beats/min).St-t abnormal changes; Serum troponin I showed 2677.00pg/mL, and the patient was diagnosed with acute coronary syndrome. The patient and his family were informed of his condition and recommended to undergo coronary angiography. After refusing to undergo coronary angiography, he was hospitalized in the First Affiliated Hospital of Shaanxi University of Traditional Chinese Medicine. The patient had a history of "hypertension" for more than 30 years, with the highest value reaching 232/160mmHg. The patient took leamlodipine tablets orally, and his blood pressure was well controlled. A 7-year history of "cerebral infarction"; History of chronic renal insufficiency for 5 years, oral Bailing capsule for a long time; He had appendectomy more than 50 years ago. After discharge, he took orally clopidogrel tablets (75mg, Po, QD), aspirin (100mg, Po, QD), rosuvastatin calcium tablets

(10mg, Po, QN), isosorbide mononitrate tablets (5mg, Po, TID) and other drugs regularly according to the doctor's advice. In June 2022, he was readmitted to the hospital and underwent cardiac B-ultrasound, which showed bilateral atrial enlargement. Left ventricular diastolic function was limited and systolic function was normal. Moderate mitral valve regurgitation, mild tricuspid valve and aortic valve regurgitation; Bradycardia; Chest CT showed enlargement of the heart shadow, left ventricular enlargement, and atherosclerosis of the aorta and coronary arteries. The patient complained of repeated oral ulcers during medication, and the effect was still not obvious after taking vitamin tablets and painkillers. The symptoms could be relieved after self-stopping clopidogrel tablets for several days. Xian Zheng see: Intermittent chest tightness, shortness of breath, on both sides of the tip of the tongue, buccal and labial medial mucosa is seen here in a number of sizes of round or oval concave ulcer, peripheral slightly reddish, pain is difficult to eat, dry mouth, fatigue, I have a cough, sputum less, spirit, not for eating, occasional abdominal distension, night take general, normal of urine, stool soft, the quantity is little, has no obvious change in body weight. Biochemical test results.

Table 1. Blood routine examination

Index	Numerical value	Unit
MCH	26.6 ↓	pg
MCHC	314 ↓	g/L
PLT	436 ↑	10 ⁹ /L
MPV	0.45 ↑	%

Table 2. Coagulation six+BNP

Index	Numerical value	unit
Fbg	5.07 ↑	g/L
BNP	428.00 ↑	pg/mL

Table 3. Liver and kidney function +blood fat

Index	Numerical value	Unit
ALB	38.0 ↓	g/L
A/G	1.1 ↓	/
HDL-C	0.89 ↓	mmol/L
Crea	116 ↑	umol/L
UA	434 ↑	umol/L
eGFR	52.42 ↓	ml/min/1.73m ²

Check the tongue pulse: the tongue is dull, the moss is white and greasy, the pulse string. By reviewing the literature and considering that the patient had no history of recurrent oral ulcer, it was considered that the recurrent oral ulcer was caused by oral clopidogrel tablets. In order to prevent thrombosis, clopidogrel tablets are not considered for the time being. With the consent of the patient, clinical symptomatic treatment with traditional Chinese medicine is given. The specific prescription is as follows(unit:g)

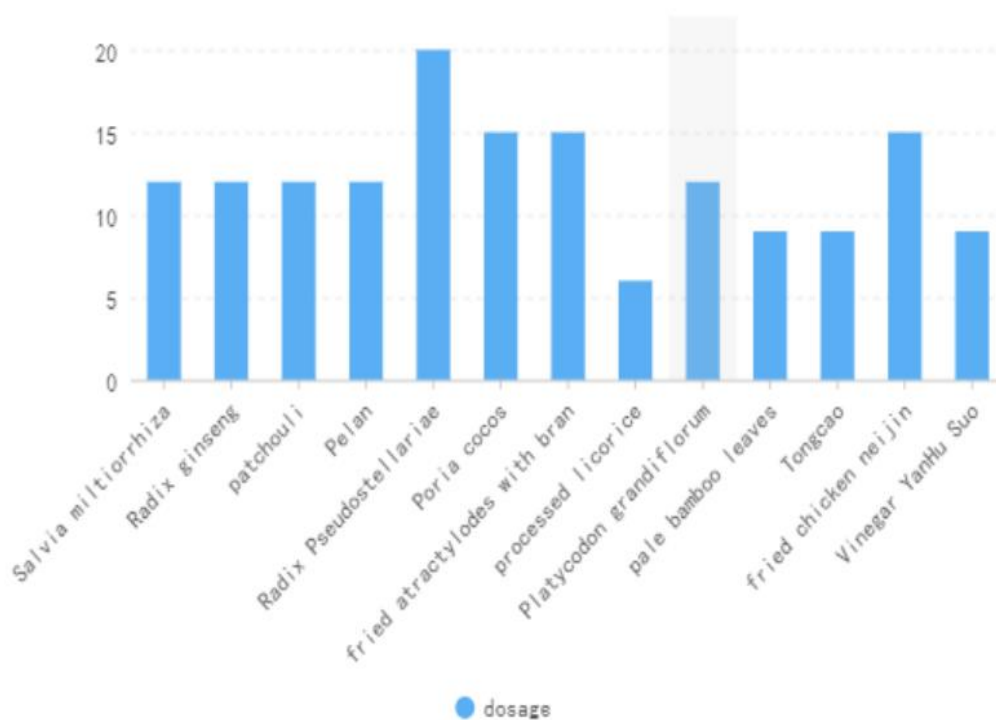


Figure 1. Various drugs and doses

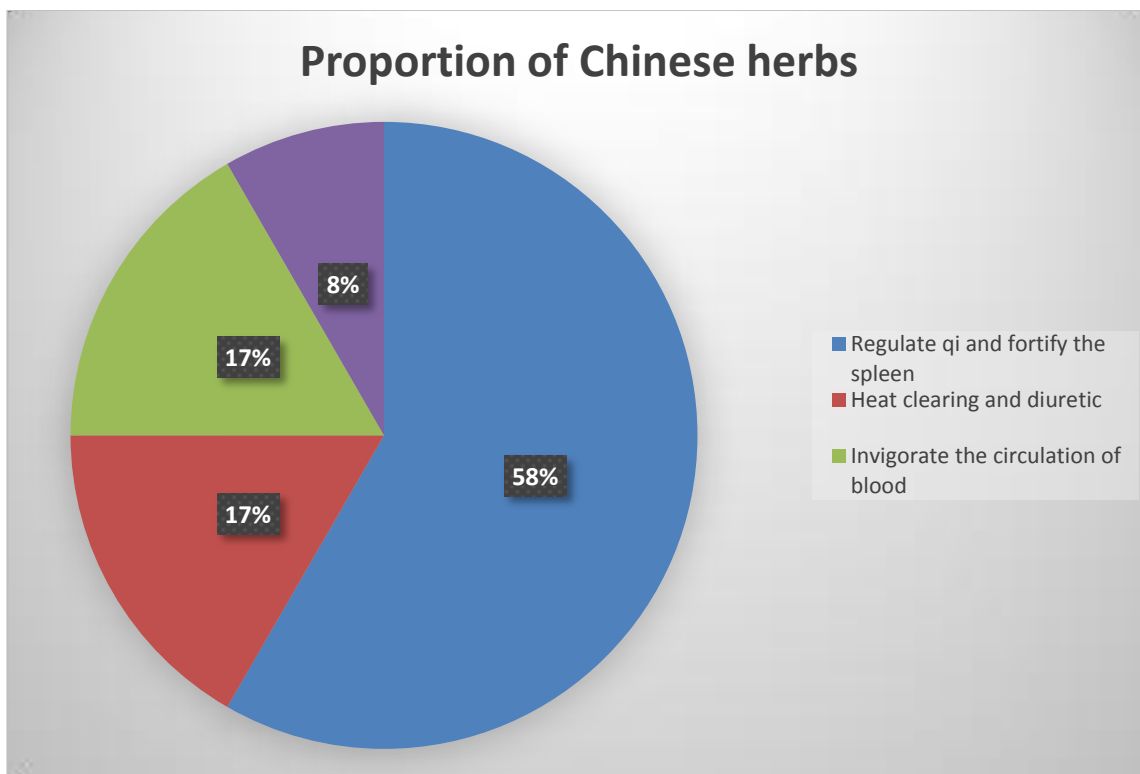


Figure 2. Proportion of Chinese herbs

9 doses, 1 dose per day, 400ml in water, and warm in the morning and evening. The ulcer area gradually decreased, and the effect was remarkable.

2. Case Analysis and Medication Characteristics

This medical record belongs to the category of "aphthous ulcer" in traditional Chinese medicine. The spleen opens its orifice in the mouth, and its splendor is in the lips. If the spleen deficiency loses its ability to raise the Qing, it cannot nourish the lips and mouth, so it becomes an ulcer. The tongue is the heart of the miao, if the heart fire on the inflammation, fumigation at the mouth, then mouth chyme tongue sore. The patient is old and frail, and the disease is lingering, recurrent attacks, and long-term medication, gas consumption is damaged, hurt the spleen and stomach. Therefore, the disease is mixed with the deficiency and the real, with the heart fire as the real, with the deficiency of the temper as the virtual, both the deficiency and the real. The fiery evil burns the body fluid, so see dry mouth; Spleen loss of health, qi disorder, often abdominal distension, loss of appetite and other symptoms, even burnout; Spleen qi deficiency, water and liquid stop gathering, easy to produce phlegm and dampness, dampness and inner sleepiness, affecting the promotion of lung, so see chest tightness, cough, less phlegm; Li Gao, a doctor in the Jin Dynasty, said in "On the Rise and Fall of the Spleen and Stomach" : "All diseases are born from the decline of the spleen and stomach". Therefore, attention should be paid not to damage the spleen and stomach in clinical treatment. Therefore, the treatment is mainly to strengthen the spleen and qi, supplemented by clearing the heart and reducing the fire, and the decoction of Sijunzi and guide red powder is used to add and reduce: the prince medicine Radix Stellariae can nourish the spleen and lungs, and improve qi and jin. Compared with ginseng, codonopsis pilosula and American ginseng, which have the effect of nourishing qi and jin, its tonic medicine is poor, but its body moistening is and it is suitable for long-term use by patients with long-term illness. In addition, because patients with deficiency syndrome take tonics in summer, they are afraid of the hot weather mixed with medicine to trigger the internal fire, so they use Radix pseudostellariae Radix Qing to supplement and strengthen the body; I with poria cocos, atractylodes atractylodes, fried chicken gold sweet is a

consider the past history of chest arthralgia, accompanied by salvia miltiorrhiza to promote blood circulation and relieve pain, Xuanshen to reduce fire and detoxify, Yanhusao vinegar to help salvia miltiorrhiza to promote blood circulation and relieve pain; In long summer, moisture is in season, and dampness is easy to invade the spleen, and the spleen likes dryness and hates dampness. Therefore, the medicine should be used during the season. Add appropriate amount of cablin and Perlan to smell the dryness and dampness of the spleen. Platycodon grandiflorum, bitter, flat, loaded with drugs up, can promote lung expectorant, "Compendium of Materia Medica" contained in the "main mouth and tongue sores" a use; Take a little Gan Han taste light bamboo leaves, Tongcao to clear the heart diuretic, guide the heart fire down; In the prescription, processed licorice is used with radix pseudostellariae , atractylodes and poria cocos, to enhance the effect of strengthening the spleen and strengthening the MIDDLE, and to reconcile the various drugs, to prevent weak bamboo leaves, TONGCAO cold injury to the stomach, to make medicine. All kinds of medicine, so that the fiery evil removed, temper can be healthy, mouth and lips caring, then aphthous healing.

3. Case Discussion

3.1. What's the Cause of the Patients with Recurrent Oral Ulcer in this Case

Modern medicine Recurrent Aphthous Ulcer (RAU), also known as Recurrent Aphthous Stomatitis (RAS), is a chronic inflammatory ulcerative disease of the oral mucosa. Its typical symptoms are single or multiple recurrent painful erosion or ulcers on the lips, tongue tip, tongue

edge and cheek, with an incidence of about 20% in the population [1]. At present, medical studies on the etiology of RAU show that the etiology of recurrent oral ulcer mainly focuses on psychological factors, dietary factors, immune factors, genetic factors, oral hygiene factors and bacteria [2]. The treatment mainly takes symptomatic treatment such as topical application of drugs to relieve patients' pain, and most of the topical drugs contain antibiotics, anesthesia and hormones. After long-term repeated application, the toxic side effects will still attract the attention of patients [3]. However, in Chinese medicine, oral ulcer belongs to the traditional Chinese medicine "mouth sore", "chyme", "mouth broken" and other categories.

The name is first seen in "plain question • Qi alternating great theory", "the age of gold is less than, the fire is line....." "Folk disease aphthous ulcer" is the earliest description of oral ulcer by ancient Chinese doctors [4]. Chao Yuan Fang in the Sui Dynasty wrote in his book on the Symptoms of Various Diseases • Symptoms of oral and tongue sores: "The hand is less Yin, the meridian of the heart is also, the heart is through the tongue; Foot Taiyin, spleen meridian also, temper through the mouth. The government is hot and dirty, heat multiplies the heart and spleen, and qi flushes the mouth and tongue, so the mouth and tongue get sores." Wang Tao in the Tang Dynasty "Wai Tai Mi Yao" contained "hot in the heart and spleen, often suffer from oral sores, the sudden onset of the difference, the accumulation of years is not the difference." All clearly pointed out that the cause of aphthous ulcer was hot heart and spleen. This case is reviewed. Since the diagnosis of coronary heart disease, the patient regularly took conventional doses of antiplatelet and antihypertensive and lipid-lowering drugs, during which oral ulcer occurred, and the attack was repeated. Observe the test indicators, blood routine, liver and kidney function did not show obvious abnormalities, ask for light diet, night rest, timely oral care, immune, diet, oral hygiene and other factors can be excluded; The use of drugs was checked. Levoamlodipine tablets and Bailing capsules were taken orally for a long time before the occurrence of recurrent oral ulcer, and no obvious adverse reactions were reported. In addition, there was no recurrent oral ulcer in the past medical history, so the effects of these two drugs could be excluded. Other oral drugs, aspirin, rosuvastatin calcium tablets, gastrointestinal system discomfort is the most common adverse reaction, isosorbide mononitrate tablets are more headache, and has not been reported to be associated with oral ulcer. Since the patient's symptoms can be relieved after stopping clopidogrel tablets by himself, relevant reports of oral ulcer cases caused by clopidogrel tablets were retrieved by literature review, and the patient's medication time was closely related to the occurrence of oral ulcer, which could be clearly diagnosed as simple oral ulcer. Therefore, the patient was considered to have had recurrent oral ulcers caused by clopidogrel tablets.

3.2. The Advantages of Traditional Chinese and Western Medicine in the Treatment of Recurrent Oral Ulcer Caused by Clopidogrel Tablets

At present, although the clopidogrel to oral ulcer mechanism is not clear, need further exploration, but in clinical practice in addition to pay attention to identify other related diseases can cause oral cavity ulcer, for daily intolerance to the patients, may use for Greg, timely replacement. Ticagrelor is a new antiplatelet drug. Compared with clopidogrel, ticagrelor has a stronger inhibitory effect on platelets, which can play a better role in drug efficacy, and then inhibit thrombosis while improving the therapeutic effect [5]. At the same time, the occurrence of such cases has aroused more attention and vigilance of clinical medical staff. It is necessary to fully do a good job in the publicity and education activities of patients, avoid the accidental risk of drug withdrawal without the consent of clinicians, and reduce the occurrence of cardiovascular adverse events. Traditional Chinese medicine, for recurrent oral ulcer is divided into internal and external treatment. Song Dynasty "Shengji Zonglu" said: "the mouth sore, from the heart and spleen heat, air

rushed to the coke, smoke the mouth and tongue, pretending to be sore also. There is also weak stomach gas, grain gas less, empty Yang on the hair and for the mouth sore, not to be treated, should ask for its received this also. "It is of great guiding value to clinical practice to point out that there are some diseases of aphthous ulcer. Sun Xingli [6] et al. analyzed Dai Yongsheng's medication rules for recurrent aphthous ulcer. Dai Yongsheng [7] believes that the occurrence of recurrent aphthous ulcer is related to the disorder of the five zang organs, which is most closely related to the heart, spleen and kidney. The main cause of recurrent aphthous ulcer is the spleen. The pathogenesis of recurrent aphthous ulcer is mostly weakness of temper and hot floating, that is, "earth deficiency and fire floating", and the treatment is to "nourish earth and bury fire". Now the patients with this disease to temper weakness, heart fire on the inflammation for the real, study its pathogenesis is a mixture of deficiency and reality. So first to Yiqi spleen, the first choice of four gentleman soup; Float fire for the heart fire, then to guide red powder. External treatment also has its advantages. In Zhu Yongfu [8] et al. Research progress in recent years Chinese medicine external treatment to treat recurrent oral ulcer, Qin Xiaolin [9] statistics 670 patients with recurrent oral ulcer ulcer powder (calcined gypsum, frankincense, myrrh, catechu, gallnut, cortex phellodendri, radix scutellariae, radix rehmanniae, asarum, borneol) drug amount above baked-on, altogether grind powder, spray on the sore, 3 hours, The cure rate was 40.96% and the effective rate was 100%. Zhang Suna et al. [10] used gallnut as the main drug to prepare the gallnut sustained release drug film. In the animal experiment of the white rabbit oral ulcer model made with 40% glacial acetic acid, they found that the gallnut treatment group could significantly shorten the course of disease and promote ulcer healing. Chocolate [11] using tripterygium wilfordii combined external ulcer treatment, 240 patients with recurrent oral ulcer, the total effective rate was 93.3%, and that tripterygium wilfordii with topical ulcer powder with regulating the body's immune function and CD3+, CD4+, CD8+ T cells of balance function, better promote the oral cavity ulcer healing, effectively extend the cycle of oral ulcer recurrence. Yang Jinming [12] used the combination of acupuncture and medicine (Sanyinjiao, Chengjiang, Laogong and Hegu acupuncture, combined with Danshu Fuling decoction) to treat 24 cases of oral ulcer. Among the 24 cases, except one case was ineffective due to the treatment of advanced lung cancer, the remaining 23 cases had ulcer healing after one course of treatment, and the pain disappeared completely or only had discomfort. Chen Jun [13] used Kangfuxin liquid (a traditional Chinese medicine biological preparation extracted from the dried whole insect of *Periplanta Americana*, rich in peptides, mucosine, polyols and other bioactive substances, which can promote cell reproduction, angiogenesis and improve wound microcirculation) to treat recurrent oral ulcer. The control group was gargled with 10mL 0.2% chlorphenidine gargle. Results The total effective rate of the treatment group (91.18%) was significantly better than that of the control group (61.76%) ($P < 0.05$). Zhuo Ya [14] used embedding therapy to select points. A group of points included Weishu, Tuopishu and Zusanli; Two groups of acupoints: Quchi, Sanyinjiao. The total effective rate of 30 patients with recurrent oral ulcer was 93%. Zhang Haiyun [15] compared the use of xidi iodine lozenges combined with watermelon cream spray (experimental group) to treat oral ulcer with Xidi iodine lozenges alone (control group), and the effective rate was 95.8% in the experimental group and 79.5% in the control group. There was statistically significant difference in the effective rate between the two groups ($P < 0.05$). In addition, compound grass coral lozenges and watermelon cream tablets are commonly used in clinical practice. Corrosive drugs such as 10% silver nitrate or 50% Tincture of trichloroacetic acid can cauterize the wound, and even for patients with obvious pain of long-term nonunion ulcer can be treated with local submucosal blocking injection. The application of wound dressing, acupoint application and acupuncture and other methods is diversified, and the therapeutic effect is remarkable. To sum up, treatment in clinical practice for oral clopidogrel area caused by repeated relapsing oral ulcer, in removing basic causes after

reaching safety status, encourage more medical personnel USES the thinking of traditional Chinese medicine overall sits, syndrome differentiation and treatment, rational use of traditional Chinese medicine to alleviate pain patients, by combining traditional Chinese and western medicine treatment to achieve the best curative effect.

Funding

This article is not supported by any foundation.

Data Availability

Data sharing is not applicable to this article as no new data were created or analysed in this study.

Conflict of Interest

The author states that this article has no conflict of interest.

References

- [1] Shang Zhizhong, Wang Anan, Gao Xiaotong, Liu Tinghua. *Study on the Etiology of Recurrent Oral Ulcer. J general stomatology electronic journal*, 2019, 6 (19): 26-27.
- [2] Zhu Runqiu, Lin Xuxin, He Jiawei. *The Etiology and Clinical Treatment of Recurrent Oral Ulcer. Heilongjiang med*, 2020, 44(2):287-288.
- [3] Zhang Xianmei, Sun Qiguo. *Study on the Pathogenesis and treatment of oral ulcer. Shi zhen national medicine and traditional Chinese medicine*, 2013,24 (10):2495-2497.
- [4] Cheng Wang, Zhou Yiqun, Chen Renshou. *Chinese Medicine Differentiation and Treatment and Tracing of Oral Ulcer in Narrow Sense. Journal of changchun university of Chinese medicine*, 2014, 30(6):1161-1163.
- [5] ZHOU Lijuan, Cao Wei, Zhan Feng, et al. *Effects of Gene-Directed Clopidogrel and Ticagrelor on Inflammatory Factors, Platelet Aggregation and Prognosis in Patients with Acute Coronary Syndrome After PCI. Chinese journal of Hospital Pharmacy*, 2021,41(4):383-389.
- [6] Sun Xingli, Ou Jiangqin. *Analysis of the Medication Rules of Dai Yongsheng in the Treatment of Recurrent Aphthous Ulcer Based on Traditional Chinese Medicine Inheritance Computing Platform. Hunan Journal of Traditional Chinese Medicine*, 222, 38(7):32-36.
- [7] Dai Yongsheng. *Analysis of 224 Cases of Recurrent Aphthous Ulcer Treated by Five Elements of Traditional Chinese Medicine. Journal of Guiyang College of Traditional Chinese Medicine*, 2018,40 (4):46-48.
- [8] Zhu Yongfu, Mei Lijun, Xie Zhijun. *Heilongjiang Traditional Chinese Medicine*, 2014,(6):69-70.
- [9] QIN X L. *Study on Rational use of Chinese Medicine Ulcer Powder in the Treatment of Recurrent Oral Ulcer. Chinese Journal of Medical Innovation*, 2013,10 (4) : 100-101.
- [10] Zhang Suna, Tang Rongyin, Zhang Yongmei, et al. *Histological Observation of Chinese Gallnut Sustained Release Drug Film in Treatment of Recurrent Aphthous Ulcer. Journal of clinical stomatology*, 2013,29 (7): 397-399.
- [11] Yang Yanxia, Liu Hongquan. *Clinical analysis of Tripterygium Wilfordii Combined with Topical Ulcer Powder in the Treatment of Recurrent Oral Ulcer. Chinese journal of modern drug application*, 2013,7 (20): 134-135.
- [12] Yang Jinming. *chinese Journal of Acupuncture and Moxibustion*, 2012,32 (1): 46-46.

- [13] Chen Yun, Li Zhiyan. *Clinical Observation of Kangfuxin Liquid in the Treatment of Recurrent Aphthous Ulcer*. *Chin J med med*, 2013,28 (9): 288-2801. (in Chinese)
- [14] zaoya. *Treatment of 30 Cases of recurrent Afuta Ulcer with Suture Embedding Therapy*. *Chin J practical med*, 2013,8 (9): 35-36.
- [15] Zhang Haiyun. *Effect of Xidi Iodine Buccal Tablet Combined with watermelon Cream Spray on Oral Ulcer*. *Jilin Medical Journal*, 2014,35 (9): 1887-1887.