

A Case of Essential Thrombocytopenia Treated by Professor Wang Xiaoyan using Fu-evil Theory

Fan Liu^{1,a}, Guonian Li^{1,b}, Xianyi Luo^{1,c}, Yifo Wei^{1,d}, Yihan Liu^{1,e} and Xiaoyan Wang^{2,f*}

¹*Shaanxi University of Traditional Chinese Medicine, Xianyang 712046, Shaanxi, China*

²*Xi'an Hospital of Traditional Chinese Medicine, Xi'an 710021, Shaanxi, China*

^a1119554774@qq.com, ^b1462971862@qq.com, ^clucklyblue@163.com, ^dweiyifo852963@163.com, ^e790020831@qq.com, ^fwxiaoyan3046@163.com

* *corresponding author*

Keywords: Essential Thrombocytopenia, Fu Evil, Cimicifugae and Carapacis Trionycis Decoction, Yang Poison

Abstract: In this case, the main diseases of the patient with essential thrombocytopenia were due to external heat, internal injury of the spleen and stomach, and the infiltration of Fu evil into the collateral channels after a long illness. Professor Wang Xiaoyan, the tutor, treated the patient based on the theory of Fu evil, and the treatment was based on the method of supporting Fu evil, clearing heat, detoxifying, and cooling blood. The main prescription was Cimicifugae and Carapacis Trionycis Decoction, which was cut according to the syndrome to make Fu evil penetrate, and the condition was healed.

Essential thrombocytosis (ET) is a clonal disease of hematopoietic stem cells, with significantly increased platelet count and abnormal function in peripheral blood. It is one of the myeloproliferative tumors, and megakaryocytes proliferate in the bone marrow, also known as hemorrhagic thrombocytosis [1]. The pathogenesis of this disease has not been completely clarified, and the clinical onset is slow. The patient may not show any symptoms in the early stage, but it is only accidentally found in the routine blood examination. The main clinical manifestations (Figure 1) are bleeding or thrombosis, which can be accompanied by fatigue, splenomegaly, and numbness of the hands and feet [2]. The Western medicine treatment of this disease mainly focuses on antiplatelet prevention and treatment of thrombotic complications and reduction of platelet count. Drugs such as bone marrow inhibitors, interferon, antiplatelet, or platelet apheresis are selected (Figure 2) [3]. The clinical progress is slow and remains benign for many years, but long-term medication is needed. This patient was found with a facial rash fused into a sheet as the main clinical manifestation, and then the examination was completed.

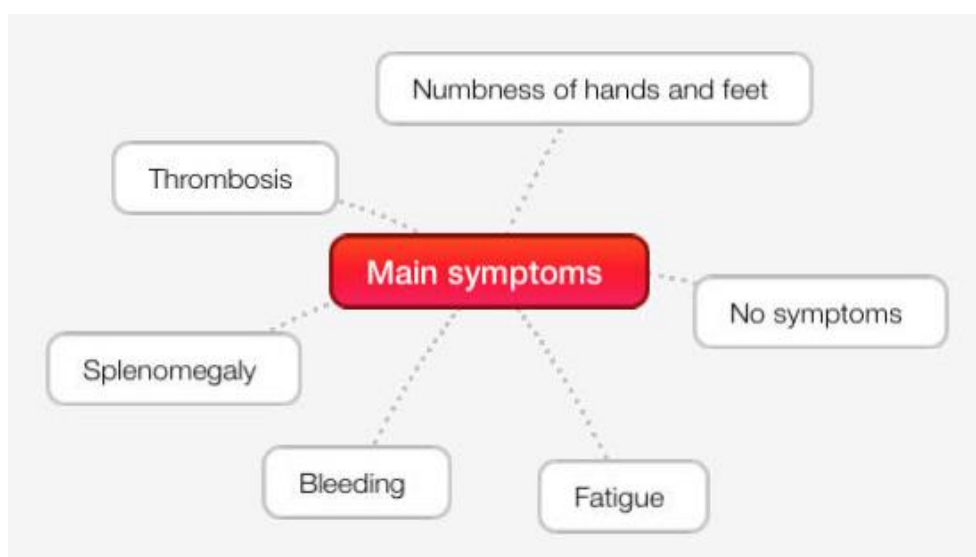


Figure 1. Main symptoms

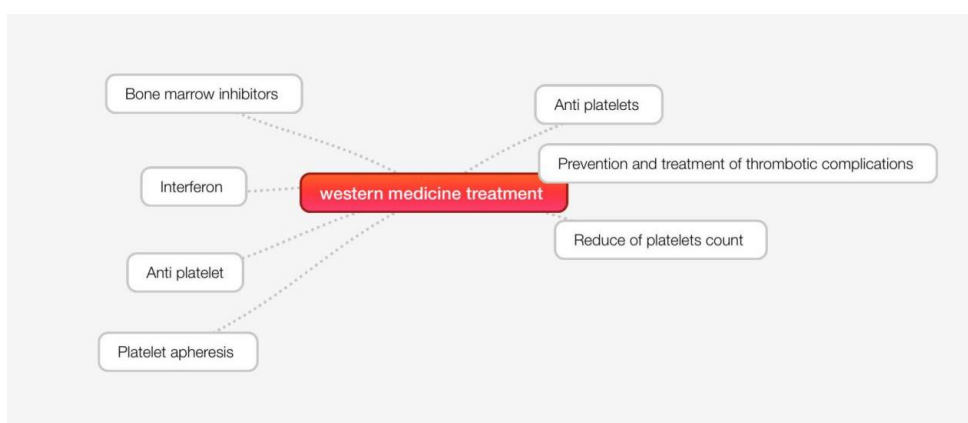


Figure 2. Western medicine treatment

1. Medical Records

Patient Zhang, female, 60 years old, date of initial diagnosis: On September 23, 2019. She was admitted to the hospital because of "intermittent head and face red rash for more than 10 years, aggravated for half a year". She developed head and face red rash for no obvious reason more than 10 years ago. The rash was patchy and fused to the zygomatic, alar, and nasal region, which was higher than the skin surface, with obvious itching and pain, and scattered to the forehead, jaw and scalp. The patient was treated at the Institute of Hematology, Xi 'an Central Hospital. The routine blood examination showed that: The white blood cell count (WBC) was $21.56 \times 10^9/L$, the hemoglobin concentration (HGB) was $163g/L$, the platelet count (PLT) was $466 \times 10^9/L$, and the bone marrow biopsy was completed. The patient was diagnosed as "essential thrombocytopenia" and was treated with oral aspirin enteric-coated tablets for a long time. After that, the patient repeated blood routine examination showed that PLT: $400-600 \times 10^9/L$, sought medical treatment from many sides, intermittent oral Chinese medicine treatment, sometimes relieved, but did not get better, nasal alar, nasal paraphernalia red rash always existed, every cause of fatigue, eating irritating food, insolation and other aggravations. After half a year ago, due to travel insolation suddenly appear afore-mentioned symptoms worsen, head facial rash fusion is patchy, with two

zygomatrics, the alar and nasal must give priority to, the forehead, the chin and scalp scattered, because of the disease, patients with depressed, and don't want to communicate with people, food, general, body emaciated, sleep well, dry stool, urine. Usually irritable, formerly fat, nearly ten years of weight loss.

The patient has been engaged in cooking for more than 30 years and is now retired. Find the tongue light dark slightly fat, thin white moss, sublingual varicose, blood stasis purple, small capillaries Yu red. Double inch pulse floating, pun pulse string slightly tight, slight top finger, right pulse heavy press weak, double ruler pulse weak. Diagnosis of traditional Chinese medicine: Yang toxin leads to spot syndrome differentiation type: heat toxin in branches of channels, liver and kidney deficiency treatment: Through down evil, clear heat and detoxify, nourish liver and kidney. Prescription of Cimicifugae and Carapacis Trionycis Decoction, the specific composition is as follows: Cimicifugae 45g, Vinegar turtle armour 20g, decocted first, Angelica sinensis 30g, Chinese prickly ash 6g, processed licorice 30g, realgar 0.5g, raw Pinellia pinellia 30g, Magnolia officinalis 15g, Coptis coptidis 10g, Forsythia 15g, raw rehmanniae 30g, honeysuckle 30g, Cassia twig 10g, raw gesso 15g, Stephania tetrandra 15g, Curcuma vinegar 20g, ginger 15g, 5 doses, watering 400ml, taking in the morning and evening.

Second diagnosis: On September 27, 2019, the facial erythema was significantly improved. The area of zygomatic erythema decreased, the nasal alar and nasal quasi-erythema remained, and the scattered erythema on the jaw and forehead subsided. Keep the square as before, deducting forsythia, Stephania tetrandra, add Yu jin 30g, asarum 10g, Huangbai 10g, astragalus 45g, Cornus officinalis 3g, raw ochre 15g, ginger charcoal 15g, radice cyathulae 30g, red peony 30g, char licorice 30g, 6 agents, water decocted 400ml, taking in the morning and evening.

Third diagnosis: On October 28, 2019. Blood routine examination was performed on October 24, 2019. WBC was $13.48 \times 10^9/L$, PLT was $418 \times 10^9/L$, and HGB was 148g/L (Figure 3). The patient's symptoms were aggravated again after eating starch solution vegetables. Cimicifugae and Carapacis Trionycis Decoction was continued to be added or subtracted, and the drug composition was as follows: Astragalus 45g, Trionyx sinensis 20g, Angelica sinensis 30g, cohosh 60g, raw radices rehmanniae 60g, fleece flower root 15g, Evodia officinalis 6g, Chinese prickly ash 6g, cassia twig 15g, red peony 60g, radix curcumae 30g, chrysanthemum 24g, salt phellodendri 10g, ginger charcoal 15g, ginger 15g, jujube 15g, licorice 30g, the rhizome of Chinese goldthread 10g, dandelion 30g, Stir-fry grain, malt 10g, cinnamon 10g, 7 doses, decocted 400ml in water, and taken twice in the morning and evening.

The fourth diagnosis: On November 7, 2019, the facial erythema was significantly improved, and the amount of erythema was reduced. The nasal alar and nasal quasi-erythema existed, the scattered erythema on the jaw and forehead subsided, and the scalp erythema always existed. Prescription of Cimicifugae and Carapacis, Trionycis decoction and Yinhuo decoction, the specific drug composition is as follows: Cooked Rehmannia rehmannii 90g, Morbergenia officinalis 30g, Poria Coho 30g, Asparagopsis japonicum 30g, Ophiopogonis 30g, Schisandra chinensis 10g, raw Pinellia pinellia 30g, Coptis coptidis 10g, Wumei 23g, Phellodendron phellodendri 10g, Amomicum amomicum 15g, Honeysuckle 60g, ginger charcoal 10g, red peony 30g, cassia twig 15g, Astragalus membranaceus 45g, periostracum cicada 15g, Cimicifugae 60g, Angelica sinensis 30g, fried atractylodes 45g, ventriculi galli mucosa 15g, prepared RADIX ET RHIZOMA RHEI with wine 3g, licorice 30g, vinegar turmeric 20g, wood incense 10g, 6 doses, decocted 400ml, in the morning and evening twice. Up to now, the erythema on the face and head subsided, and only the nasal, alar, and paranasal rashes remained, with no other symptoms.

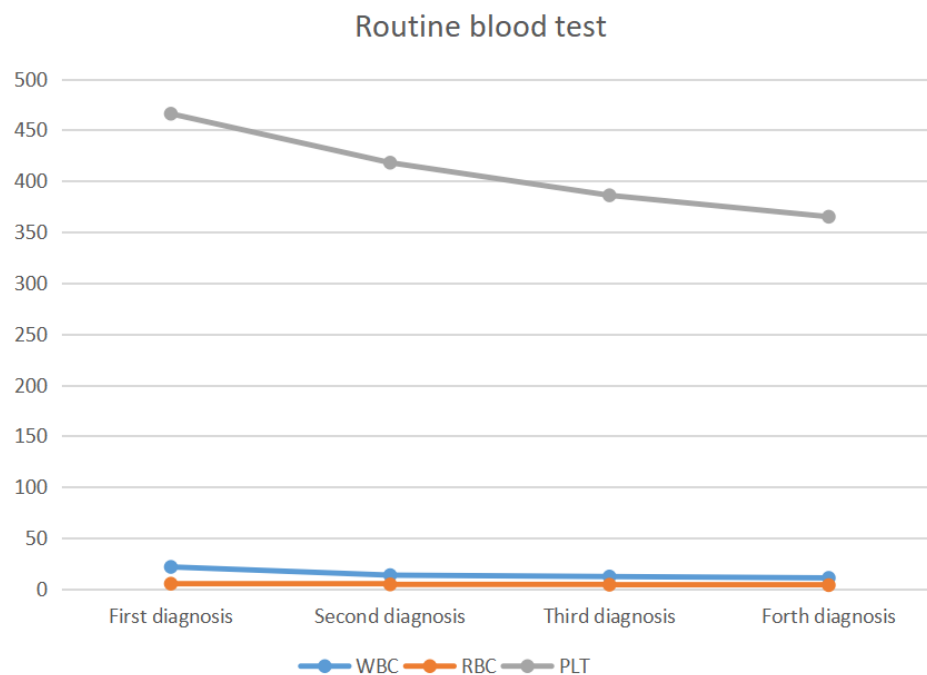


Figure 3. Routine blood test

2. Discuss

There is no name of "essential thrombocytosis" in traditional Chinese medicine, but there are a lot of descriptions of its clinical manifestations, which can be classified into the categories of "aemia", "asthenia", "Yang toxin" and "accumulation" in traditional Chinese medicine [4]. In this case, the rash on the face was higher than the skin and fused into a piece as the main clinical manifestation. In the *Jingui Yaolüe*, the treatment of Yin-yang virus disease, Yang toxin was the disease, the face was red as Jin Wen, the throat was sore, the saliva was pus and blood. Five days can be treated, seven days can not be treated, *Cimicifugae and Carapacis Trionycis Decoction* master ", although this patient has no sore throat, salivary pus and blood witness, but the facial erythema and the provision of "face red as Jin When" is the same, so the main prescription is *Cimicifugae and Carapacis Trionycis Decoction*.

2.1. Cause Analyses

2.1.1. Exogenous Pathogenic Fire

The patient had been engaged in cooking for a long time, lived near the fire for a long time, the evil of external heat for a long time, when the sweat hole dilated layer upon layer of pressure on the body, lying in the body, consumption of bodily fluids, fluids, blood, so the patient was fat at first, and then gradually lost weight, wasting. Volt evil meets the new sense of arousal, and then the disease always belonging to the sense of evil and later. The *New Book of Fu Xie* [5] says, "The feeling of the six evils does not mean the disease. Those who develop in the rear are always called *Fu Xie*, while those who have developed cannot be cured. The disease is hidden and is also called *Fu Xie*." The course of the patient for more than 10 years, the sense of evil day, deep in the body, the rear hair, and each treatment did not go to the heat of its volt evil, can not do to drive its evil, the

treatment stopped abruptly, encounter external heat evil easy to trigger the body vol evil, so clinical see its symptoms recurrent.

2.1.2. Internal Injuries Spleen and Stomach

The patient was fat in the past, related to his work as a chef, overeating fatty, sweet, and greasy products, damaging the Yang in the spleen and stomach, Yang deficiency caused internal cold. The spleen and stomach are the acquired root, the granary officer, the center and the main soil, and the hub of the rise and fall of the activities of qi. The acquired root damage, the innate root, liver, and kidney need to rely on the acquired root, spleen, and stomach to nourish the damage of the Yang in the spleen and stomach, and the long-term illness will cause liver and kidney deficiency. In a preliminary study on the treatment of cold and dampness in camp [6], Mr. Wu Xiongzhi said, "Yang deficiency of the heart, spleen and kidney, three zang organs, endogenous cold evil, crouching in camp; or the body of deficiency cold, outside by dampness evil, transmitted in camp ", spleen and kidney Yang deficiency, cold evil endogenous, positive Qi internal injury, evil Qi invagination, positive Qi can not drum evil out, clinical show temporary false healing potential, after recurrent attack, this is also the characteristics of Fu evil pathogenic.

2.1.3. Macronosia into Branches of Channels

Ye Tianshi pointed out in the Medical Case of Clinical Evidence Guide [7] that: "At the beginning of disease in the gas, will and blood", "early as in the air, the long blood in the complex yet, disease pain time passes into the blood vessels", also illustrates the long illness in the winding of the blood disease, facial rash, disease in the blood, and heat evil in the volt by cremation poison, fell on the body, consumption, so the patients for nearly 10 years of angular, after the onset of mainly happens on the sun, the body heat of evil in the lead, So the relapse. Check tongue light dark slightly fat, thin white moss, spleen Yang deficiency transport has no right, water wet stop, cold wet endogenous, so see dark fat tongue, sublingual branches of channels varicose purple, small capillaries Yu red in line with the clinical manifestations of Fu evil in the branches of channels.

2.2. Characteristics Analysis

Cohosh turtle shell Shang Yifang began with the raising of flax and the main licorice role in middle earth, cohosh advocate Yang Ming, lunar, two classics, rose by indecent, construct evil, detoxification, the rule of temperature and complete [8], Yin and Yang are two disease can spread fire detoxification, scattered YongZu litres of gas, main licorice thick rustic to achieve the meaning of "v" soil fire, angelica, turtle shell are the main into the liver meridian, invigorate the circulation of the blood stasis, Because the Shengma only go Yangming, Taiyin two by gas points, so will be accompanied by angelica in the blood, the poison in the broiling licorice collaterals, add a small number of turtle armor guard camp god, Shu pepper, realgar and other violent products, in order to challenge through the table, without the effect of the gods. Due to facial rash fusion into a piece, the color is bright red, considering the local Yu heat, with the addition of honeysuckle, forsythia, Gesso heat detoxification products, honeysuckle clear solution of Fu toxin, "Lei Kong processing medicine solution" pointed out: honeysuckle solution of skin poison. In Changsha Medicine Jiejie [9], forsythia is said to "clear fire and reduce fever, and benefit water and reduce dampness"(Figure 4). Gypsum can be an open table and clear Yangming by heat or gas heat. Since the patient has been ill for a long time, with a lingering emotion, raw pinellia, Magnolia officinalis, and ginger were added, and Pinellia officinalis decoction was adopted to eliminate phlegm depression and Qi stagnation. "All itching sores, all belong to the heart", so add a small amount of Coptis chinensis, Coptis chinensis is cold, the qi of the winter cold days into the foot Shaoyin kidney meridian, bitter

diarrhea heart, and treat heart fire. Combined with pulse condition, pun is a bit tight, pulse string slightly refers to, this is needed for local gas knot, Yang Ming evil heat bizu interface, so the party to add cassia twig, prevent, plaster stone, wood take out soup, continues to rule the evil local person bizu, caused by the heat to ginseng in case of fire, use raw radix rehmanniae with heat cool blood, "huang di" [10] call it can by invigorating blood, with this card.

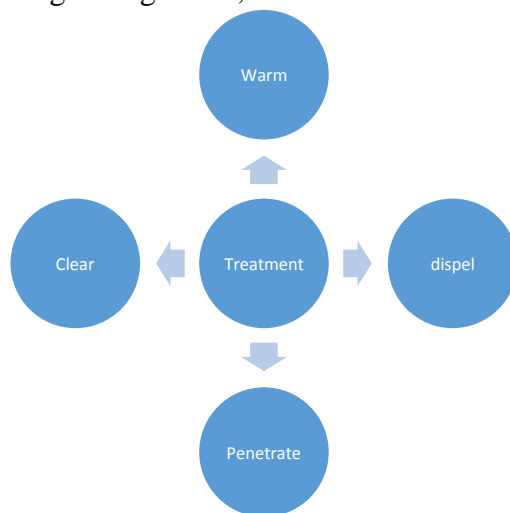


Figure 4. Treatment ways

At the second diagnosis, the symptoms of the patient improved significantly, so the main prescription continued is Cimicifugae and Carapacis Trionycis Decoction, the side to forsythia, prevent oneself, the side to add asarum, take its warm dry open, the intention of the lung and stomach. Add Yu Jin to the line Qi Jieyu, cool serum heart. "Changsha Medicine Jiejie" cloud: Ochre taste bitter, Qi flat into the foot Yangming stomach meridian, reducing the soil and in addition to the afio eer, town, Xinjin, and clear annoyance and heat. With the Chuan Niushiu to Huoxue heat down, Huang Yuan royal "jade pull medicine solution" said: its sex down. Clinically, the dosage of astragalus membranaceus exceeds 45g, which is mainly to reduce. 45g astragalus membranaceus is heavy in Li waterway, and the patient's stool is dry, so astragalus membranaceus Tongli waterway. Add ginger charcoal care coke, all drugs together, a total of Qingrehuoxue Qi stagnation, through the work of evil.

Three diagnosis: Because of careless diet, harming the ZhongYang axis, dysfunctional temper, not stomach not gas, Yang Ming can't close down, harmony in southern thermalization fire wall, so the clinical symptom is aggravating, Yang Ming is not closed, lack of water, yuan will be cold, so the party in order to clear, rhizoma coptidis, chrysanthemum, GongYing, cortex cinnamomi, radix polygoni multiflori, evodia rutaecarpa under warm, ginger, jujube in the grass to protect. It was considered as an internal injury in the diet, so stir-fried wheat malt was added to disperse food and strengthen the spleen.

At the fourth diagnosis, the patient's symptoms improved, which proved that the diagnostic idea and the direction of treatment and medication were correct. Therefore, Cimicifugae and Carapacis Trionycis Decoction was still the main prescription, combined with Yinhuo decoction, and added or subtraction of the syndrome. Li Ke, an veteran practitioner of TCM in the clinical syndrome to make good use of this prescription for the treatment of kidney water insufficiency, fire does not return to the original produced by the syndrome, and discussed the pathogenesis of this prescription: "Kidney for congenital , send the life door really fire,defi fire and water embrace, Yin Pingyang secret. Water feet or hidden in the next warm viscera, leading a gasification; water cut in the fire lost its system, such as shallow water do not keep the dragon running away from the position ". And

put forward: "water deficit to kindling soup, Zhuang water collect fire, guide the dragon to the sea; If the water is cold, add oil and cinnamon to kindling soup, swallow rice pills first, warm dirty collect Yang, and kindling back to the original ". Phellodendron officinalis, amomum, and licorice are three materials to seal the pith, absorb the qi and return to the kidney, replenish the upper, middle and lower, and reconcile the fire and water, to be even and constant, and to be divine and wonderful. Cicada decidua, rhubarb, take Mr. Yang Li Shan's meaning of the rise and fall of cicada decidua floating and transparent, can clear the heat and solve the table, the spread of poison thoroughly, rhubarb through the Fu organs by blood stasis, push Chen Zhi Xin(Figure 5). Accompanied by Bai Shu health in the gas, the fire of the black plum collected from the position, the overall treatment, not confined to one party medicine, of the syndrome.

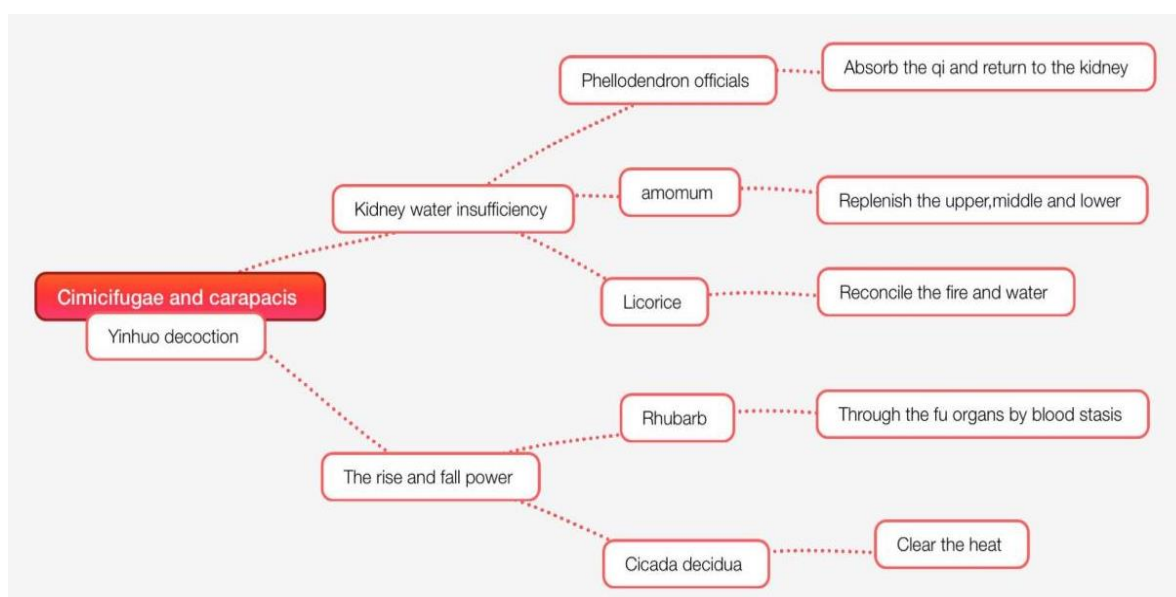


Figure 5. Analysis of the decoction

3. Conclusion

At present, the treatment of essential thrombocytopenia in western medicine mainly focuses on reduced platelets, and the short-term effect is reasonable. There are some deficiencies in long-term efficacy. Traditional Chinese medicine in the treatment of this disease, paying attention to the overall treatment, syndrome differentiation and treatment, not limited to one side of a syndrome, drug, the whole combination of all causes, regulate the human body to achieve equilibrium between yin and yang, knowing the principle of treating disease, traditional Chinese medicine treatment, reason first, clinical syndrome can be at hand. Case sharing a family of words for your reference.

Funding

There is no fund for this thesis.

Data Availability

This article has no data.

Conflict of Interest

There is no conflict of interest between all authors.

References

- [1] Ge Junbo, Xu Yongjian, et al. *Internal Medicine*. 9th Ed. Beijing: People's Medical Publishing House, 2018:598-599.
- [2] Leng H, Fang Z H, Zhang Y, et al. *Clinical analysis of 438 cases of essential thrombocytopenia*. *Chin J Hematology*, 2008(9): 587-591.
- [3] Ma Sheng, Liu Zhiqiang, Ma Yongchen. *Chinese Journal of Acupuncture and Moxibustion*, 2015, 35 (12): 1266. DOI: 10.13703/j.0255-2930.2015.12.018.
- [4] Song FuYi's. *Experience in the treatment of essential thrombocytosis*. *Research of Traditional Chinese Medicine*, 2018, 31(01):44-46. (in Chinese with English abstract)
- [5] Liu Jiren, *New Books of Fu Xie Shanghai: Traditional Chinese Medical Books, Republic of China (1912-1948)*:1.5.
- [6] Zeng Shengping, Wu Xiongzhi. *Preliminary study on the treatment of cold and dampness in camp*. *Chin J Basic Medicine of Traditional Chinese Medicine*, 2001, 7(2):14-15.
- [7] Ye Tianshi, *Clinical Evidence Guide, Medical Case Beijing People's Medical Publishing House*, 2014.
- [8] Huang Hui. *Shen Nong's Herbal Classic Journal of Clinical Chinese Medicine*, 2012, 10 (v.24): 97-97.
- [9] Li Tingkai. *3 cases of clinical differentiation and treatment of sweat evidence*. *Shanxi Traditional Chinese Medicine*, 2021, 37(12):38+40.
- [10] Peng Haiyan, Zhang Chunni, Lu Liu. *Zhang Jianping's. Experience in the treatment of essential thrombocytopenia from the perspective of toxicity*. *Shandong Journal of Traditional Chinese Medicine*, 2021, 40(08):863-866.