

# ***Observation on the Short-Term Nursing Effect of Microscope Assisted Periodontal Flap Surgery in the Treatment of Moderate to Severe Periodontitis***

**Minglei Jiang\***

*Guilin University of Electronic Technology, Guilin, China*

*\*corresponding author*

**Keywords:** Microscope Assisted, Lower Periodontal Flap, Periodontitis, Nursing Effect

**Abstract:** Periodontitis is the most common oral disease, which is one of the important reasons for people's oral teeth falling. Periodontitis can not only cause a variety of oral diseases, but also indirectly lead to physical diseases. The purpose of this paper is to study the therapeutic effect of microscope assisted periodontal flap surgery on severe periodontitis. Therefore, 48 patients with severe periodontitis during the 12-month period from 2018 to 2019 were selected as the experimental subjects and divided into the experimental group (EG, microscope assisted periodontal flap surgery for periodontitis mode) and the control group (CG, traditional periodontal flap surgery treatment of periodontitis mode) by drawing lots. After 6 months of nursing records, the clinical data of Bi, PD, Al, periodontal changes, gingivitis incidence and protease activity of perigingival oral fluid were compared between the two groups before and after treatment. In 1-3 months after the operation, the contents of Bi, PD and Al decreased compared with those before operation; the amount of gingival bleeding, the attachment around teeth and the detection depth were better than those in the control group. And with the increase of postoperative time, the amount of bleeding and tooth attachment continued to decline; as for the incidence of gingivitis, there was a significant decrease trend compared with the number of patients in the control group; the activity of salivary protease around the teeth of the experimental group was lower than that of the control group. Compared with the control group, the incidence of periodontal disease after the operation was slightly better than that of the control group. It has a broad application prospect in the medical field to avoid the breeding of foreign bodies around the teeth, gingival bleeding and other symptoms, and protect the safe growth of teeth.

## **1. Introduction**

Periodontal disease [1] is one of the oldest and most common diseases in human beings. It has a

high prevalence among the population. Epidemiological survey showed that the prevalence of periodontal disease in the general population increased with age. At the same time, the distribution of periodontal disease in the population is not uniform. Different individuals have different susceptibility to periodontal disease, and there are risk factors affecting the process of periodontal disease. Some experiments have shown that periodontitis first occurs in the accumulation and maturation of dental plaque, which will lead to inflammation of adjacent heel tissue. However, the duration and intensity of inflammation vary greatly from person to person, and from tooth position to tooth position. Some data show that only some people and part of the heel of the tooth position inflammation will develop into periodontal tissue loss, that is to say, some people's heel inflammation is more likely to develop periodontitis. According to the longitudinal observation of the patients who never brush their teeth and have no dental disease, 18% and 91% of the patients have rapid and slow onset of disease, and have severe, mild and moderate periodontitis. During the 18 years of investigation, 22% of the patients had no progress. This indicates that different individuals have different susceptibility to periodontal disease, and there are risk factors affecting the process of periodontal disease. These risk factors and periodontal disease constitute a complex relationship, not a simple causal relationship. A large number of studies have shown that plaque [2] is a necessary condition for periodontal disease, but the complexity and severity of periodontal disease cannot be explained only by plaque microorganisms.

At present, there are two risk factors of periodontal disease: congenital risk factors and acquired environmental risk factors. These problems include race, gender, genetic factors, congenital immunodeficiency, phagocytosis dysfunction, periodontal tissue syndrome, poor oral hygiene, use of phenytoin sodium, non-steroidal anti-inflammatory drugs, smoking, acquired immunodeficiency, etc. Under the joint action of some risk factors, periodontal disease will eventually occur. Objective to understand the relationship between these risk factors and periodontal disease, and to formulate the etiology, diagnosis and treatment of periodontal disease. In order to understand the influence of oral hygiene habits and related factors on patients with periodontitis, scholars have conducted a large number of studies on the pathogenic factors of periodontitis for many years. It is found that age, race, smoking, oral health and local factors, host immunity, gene and other risk factors have a certain impact on periodontitis, while gender, education level, socio-economic level and other factors are still controversial and cannot be completely determined. At present, the situation of periodontal disease prevention and treatment in China is very serious, and the prevention of periodontitis has not been carried out in an all-round way. It is still necessary to further clarify the etiology of periodontal disease and implement effective prevention. Due to the weak oral health awareness of Chinese people, it may also be related to the economic burden and consumption consciousness, while mild periodontitis is not obvious, which cannot arouse the attention of patients, so the treatment rate of patients with mild periodontitis is low.

There are many kinds of periodontal surgery, including basic periodontal surgery, periodontal regeneration surgery, and periodontal plasty and so on. Periodontal pocket [3] is one of the main treatment objects of periodontal flap surgery. The depth of periodontal pocket can be eliminated or reduced by surgical removal of a part of the periodontal pocket wall; the diseased alveolar bone can be repaired and regenerated through surgical exposure; the root surface debridement approach is added to make the root surface smooth under direct vision, and the cementum containing endotoxin and the infected soft and hard tissue can be removed. There are many different methods of periodontal flap operation in the treatment of periodontal pocket [4]. However, some operations are designed to eliminate the periodontal pocket, while others are designed to provide a root surface debridement method to make the periodontal pocket shallow. According to different surgical purposes and patients' conditions, the specific surgical design is also different. The results showed that there were still deep periodontal pockets or complex periodontal pockets after the basic

treatment, and the periodontal wall had inflammation and bleeding after periodontal exploration; the deep periodontal pocket with the bottom of treatment bag exceeding the membranous gingival joint should not be treated with periodontotomy, but should be treated with flap operation; alveolar bone defect needs bone repair or bone grafting, periodontal tissue regeneration treatment; root furcation disease with deep periodontal pocket. Patients with periodontal and root canal diseases need to be completely flattened, exposed or cut off a root under direct vision, so as to achieve the purpose of treatment of root bifurcations disease; gingival teeth range is wide, obvious hypertrophy, simple gingival tooth resection will form excessive wound, at this time, flap operation or flap operation can be used to combine gingivectomy. Therefore, for the multi root teeth with bifurcation lesions [5], the advantage of surgical treatment is that root stones and inflammatory infection can be completely removed under direct vision.

In recent years, microscope has become a new technology of precision oral therapy with its unique advantages of illumination, amplification and improving the accuracy of surgical techniques [6]. Most of the surgical areas, especially the lingual side of the posterior teeth and the distal side of the molars, are difficult to be viewed directly. In the process of microsurgery, it is difficult to adjust the position of patients and doctors, the angle of oral cavity mirror and the angle of microscope. If the adjustment time is too long, the operation efficiency will be greatly reduced, which greatly limits the development of periodontal microsurgery. At present, the application of microscope in stomatology at home and abroad is mainly focused on finding missing root canal, repairing root canal perforation, cutting instruments, dealing with calcified root canal and other dental pulp diseases, and the application of periodontal treatment is less. Periodontal microsurgery is usually performed at a magnification of 20-30. At 30 times, the motion accuracy of the hand is close to 20  $\mu$  m, and the visual resolution is close to 1  $\mu$  m, which is higher than the maximum resolution that the human eye can achieve in the conventional field of vision. Therefore, the microscope can provide excellent visual guidance to enhance the operation skills and sensitivity, which means that the surgical incision is more accurate, the flap debridement wound is relatively small, and accurate tension suture can be achieved. After the operation, clinical primary healing can be achieved, the complications are significantly reduced, and the appearance is more in line with aesthetic standards. Recently published articles have shown that the vascularization and root coverage of the flap after microsurgery are improved compared with that of the naked eye. The results show that the optical fiber illumination and amplification function of the microscope are more conducive to the extraction of dental calculus. Therefore, microscope has unique advantages in gingival membrane surgery, root debridement and crown lengthening.

In order to verify the clinical effect of microscopically assisted periodontal flap surgery in the treatment of moderate to severe periodontitis, 48 patients with severe periodontitis were selected as the experimental subjects and the periodontal flap surgery with and without microscope assistance was performed. Firstly, this paper introduces the factors of periodontitis, the reasons of using periodontal flap surgery and the application of microscope in dental surgery; secondly, it expounds the principle of periodontal flap surgery under microscope in the treatment of moderate and severe periodontitis, including the prevalence of moderate and severe periodontitis, the basic treatment methods and the basic principles of periodontal flap surgery; secondly, the experimental cases with need are compared. Finally, through the experiment, the periodontal flap surgery under the microscope was carried out more smoothly, the regeneration rate of foreign bodies in the mouth was significantly reduced, the gingival bleeding and the detection of salivary protease around the gingiva were much better than those in the control group. Therefore, microscope assisted periodontal flap surgery has a good clinical effect in the treatment of moderate to severe periodontitis, which is worthy of application in major dental hospitals.

## **2. Principle of Microscope Assisted Periodontal Flap Surgery in the Treatment of Moderate to Severe Periodontitis**

### **2.1. Prevalence of Moderate to Severe Periodontitis**

Periodontal disease is a common oral disease, and also one of the main causes of adult tooth loss. Periodontal disease is not only harmful to oral health, but also affects the general situation of patients. For example, a large number of studies have confirmed that periodontal disease and diabetes have a two-way relationship. Periodontal disease is not only a complication of diabetes, but also has a certain impact on diabetes. The World Health Organization defines oral health as clean teeth, no cavities, no pain, normal gum color, no bleeding. In the third national oral health epidemiological survey, no gingival bleeding, no periodontal pocket, no attachment loss less than 4mm were defined as periodontal health. The results showed that the periodontal health status of Chinese adults was less than 24%. The periodontal health rate of 30-50 years-old population in China is only 24.6%, which is higher in urban areas than in rural areas, and higher in women than in men. The periodontal health rate of the elderly aged 60-80 in China is 24.7%, which is lower in urban areas than in rural areas, and higher in women than in men. 42.38% of the 30-50-year-old population lost their teeth, and 83.67% of the Chinese elderly aged 60-80 lost their teeth. In the face of such results, we can see that periodontal disease has a great impact on oral health. We should actively prevent, treat and control the continuous development of the disease. There are many patients with periodontal disease in our country, most people are still in the weak stage of oral health awareness and lack of oral health knowledge, and many patients come to the doctor because of the severe periodontal disease symptoms in the middle and late stage.

### **2.2. Treatment of Periodontitis**

The systematic treatment of periodontal disease generally includes basic treatment stage, surgical treatment stage, prosthetic treatment stage and maintenance stage [7]. Basic treatment is the basis of periodontal disease treatment. Many patients with periodontal disease can skip surgical treatment and prosthetic treatment after systematic basic treatment, and directly enter the maintenance stage.

The purpose of basic treatment of periodontal disease is to control or eliminate caries and gingival inflammation and prevent further destruction of periodontal tissue. The treatment included: oral health education; supragingival cleaning treatment and root planing; treatment of dental caries and root canal apical disease, so as to retain meaningful teeth in future denture restoration and eliminate non reserved teeth; occlusal adjustment can eliminate occlusal trauma and occlusal interference. This clinical observation focuses on the basic treatment of periodontal disease in the treatment of moderate to severe periodontitis.

Before basic treatment, every patient should be tested for invasive viruses, including HIV, syphilis and hepatitis viruses. Ultrasound equipment should not be used in positive responders to prevent aerosol contamination throughout the clinic [8]. Only manual instruments can be used. At the same time, medical and health protection should be strengthened to prevent occupational contact. The correct treatment of contaminated equipment: seal directly after use, do not clean and soak. The main purpose is to prevent the cross infection between the swimming pool and the table during the cleaning process. Do not use the equipment after the first disinfection. After cleaning and soaking, the sealing bag can be used normally after high pressure disinfection. The invasive virus detection of 48 patients in this clinical observation was negative.

Before the beginning of each treatment, the patients were instructed to gargle with lipetidine mouthwash for 3 minutes. For the first time, ultrasonic scaling machine was used to complete the

whole mouth supragingival and subgingival ultrasonic scaling. After tooth washing, the residual fine broken calculus in the periodontal pocket was washed with hydrogen peroxide and normal saline. After a week of follow-up, the gingiva was used to scrape the maxillary and mandibular sides, and the root surface was flat. At 6 and 12 weeks after the end of basic treatment, patients were asked to return for follow-up. The changes of plaque percentage, PD and AI were recorded. Oral hygiene examination was carried out for patients in each follow-up visit. Patients with good plaque control were encouraged, and patients with poor plaque control were reminded and educated repeatedly.

### 2.3. Operation Principle of Periodontal Flap

First, the first incision (medial oblique incision) should be close to the gingival margin. It can be extended to both sides of the tooth according to the different needs of the surgical site. It is generally not necessary to do longitudinal relaxation incision (because the longitudinal incision often leaves scar after recovery). The epithelium and inflammatory tissue of the inner wall of the second incision were removed by curettage or the second incision (intrafascial incision) and the third incision (interdental incision). Generally speaking, no bone repair is required. Only when the bone shape hinders the attachment of gingival flap to the tooth neck, can proper bone repair be carried out. After the granulation tissue, calculus and root surface were completely removed, the gingival flap was reset in situ, and the adjacent alveolar bone was completely covered as far as possible to avoid bone exposure and reduce bone absorption. At the end of the operation, the tooth surface can closely fit with the healthy gingival connective tissue, which is conducive to healing, and gingival retraction is less after healing. In the healing process after flap operation, there are blood clots connecting gingival flap turning and root surface damaging root surface, and then four kinds of periodontal tissue cells grow and follow the root surface order. The first is dental gingival eversion; the second is connective tissue cells, periodontal ligament and alveolar bone. The growth rate and growth conditions of the four kinds of cells determine the final periodontal healing mode. In general, periodontal flap surgery will grow and combine with epithelial healing. This is because the gingival epithelium of teeth grows the fastest, which is also the most common way of healing.

The clinical manifestation of long junction epithelial healing was that the depth of periodontal probing became shallow or disappeared. In addition to the healing of long connective epithelium, gingival contraction, regression of tooth inflammation, increase of probing resistance and functional formation of periodontal supporting tissue are also the causes of periodontal inflammation [9]. Studies have shown that patients with good self-control of plaque can keep healthy for a long time, combining growth and epithelial healing. This treatment has a certain resistance to bacteria. The clinical manifestations were pink gingiva, no inflammation and shallow. Periodontal detection showed acquired attachment or increased attachment, and alveolar bone repair appeared in the vertical bone resorption. However, histological observation showed that the root surface was covered with epithelium and no new attachment was formed. Because there is no functional arrangement of the periodontal ligament fibers in the connective tissue with the long connection turned up and down, the collagen fibers are parallel to the root surface, so they are not really attached. The growth rate of periodontal ligament cells was the slowest. Only the periodontal ligament cells near the bottom of the pocket can occupy the root surface preferentially. If we can create conditions, periodontal ligament cells can preferentially grow on the king and occupy the root surface, precursor cells can differentiate into cementoblasts, produce new cementum surface roots, and have new alveolar bone and periodontal ligament fibers, which is the most ideal periodontal treatment method. However, through a large number of clinical, in the position of preoperative probing depth, few new attachments formed after flap operation. Because a small

amount of alveolar bone will be absorbed after surgery, so flap surgery will also cause a small loss of clinical attachment level. After surgery, there will be a certain degree of repair, that is, new bone formation appears in the original vertical bone absorption site. X-ray showed that the height of alveolar ridge decreased slightly, but the bone pocket became shallow or narrowed. However, whether the bone is repaired the degree of repair depends on whether periodontal maintenance is carried out regularly after surgery. If patients can follow the doctor's advice, do their own plaque control, regular periodontal maintenance, can get more bone repair. On the contrary, the amount of bone repair is little or no repair, some even continue to destroy alveolar bone.

### 3. Experimental Materials and Process

#### 3.1. Patient Inclusion

Experimental group (cognitive dysfunction and moderate and severe periodontitis group): 24 cases, including 12 males and 12 females, 10 cases of moderate periodontitis and 14 cases of severe periodontitis, met the inclusion criteria and exclusion criteria of cognitive impairment.

The control group (moderate and severe periodontitis group): 24 cases, including 12 males and 12 females, 14 moderate and severe periodontitis and 10 severe periodontitis, met the inclusion criteria of moderate and severe periodontitis and met the exclusion criteria.

The average age of patients in the experimental group was  $59.12 \pm 3.18$  years old, and that of the control group was  $54.32 \pm 3.04$  years old. All the subjects can take the initiative or with the help of others to cooperate with the questionnaire for testing. This study has passed the ethical audit of people's Hospital of China Medical University. The details of the study have been informed to the subjects or their guardians and informed consent has been signed.

Table 1. Basic information of experimental subjects

Project	Experience group		Control group	
	Moderate (n=10)	Severe (n=14)	Moderate (n=14)	Severe (n=10)
Age	59.12±3.18	56.43±2.56	62.32±1.43	54.32±3.04
Gender				
Male	6	6	4	4
Female	6	6	8	8
Education level				
Below junior high school	3	5	2	8
Junior high school or above	9	7	10	4
Smoke				
Yes	3	1	0	3
No	9	11	12	9
Drink				
Yes	5	11	12	8
No	7	1	0	4

Shown as Table 1, there is no significant difference in the proportion of men and women. The number of smokers and drinkers is more than that of junior high school, which paves the way for the operation.

#### 3.2. Selection Principle

- (1) For the inclusion criteria of moderate and severe periodontitis, refer to periodontology [10].

(2) The assessment of cognitive function is based on the brief mental state test, which is the most commonly used cognitive level screening scale at home and abroad [11]. Each MMSE is limited to 10 minutes, the full score is 50 points, the illiterate score > 23 points is normal, the primary school score > 32 points is normal, and the junior high school and above 46 points are normal.

### 3.3. Reasons for Not Selecting

(1) Other patients with neurological and mental disorders were excluded. (2) Suffering from other systemic diseases that affect cognition. (3) Other systemic diseases (such as diabetes, atherosclerosis, etc.) may affect the health of periodontal tissue. (5) There are serious hearing, visual impairment and other related diseases, communication barriers, affecting cognitive function. (6) Patients have less than 10 completely edentulous and functional teeth.

### 3.4 Observation Method of Short-Term Nursing Effect

Informed consent right of patients: each patient invited to participate in clinical observation shall sign informed consent before treatment to inform the purpose, time and procedure of clinical observation; introduce the possible benefits of the study to the subjects; explain the scope of confidentiality of patient information; inform patients whether they are fully willing to participate in the trial and can freely refuse to participate. If you agree to participate, you can exit in the middle of the course without losing the benefits you should have.

Clinical indicators: before treatment, 3 months (6 weeks) and 6 months (12 weeks) after treatment, the bleeding index, plaque percentage, probing depth and clinical attachment level were recorded. The baseline level of BOP [12] and plaque percentage were measured before the beginning of basic treatment, and PD baseline level and AI baseline level were measured one week after ultrasonic scaling, mainly to avoid the impact of calculus on the detection accuracy. The order of each measurement is BOP, plaque percentage, PD and Karl. The percentage of plaque measurements, four sites recorded each tooth: buccal, lingual, middle distally central and each tooth was recorded at six locations: mesiobuccal side, buccal center, distal buccal edge, middle tongue, lingual center and distal lingual side.

### 3.5. Questionnaire Survey

The subjects were investigated by questionnaire. The survey included:

(1) Demographic characteristics of the subjects, such as name, gender, age, residence, occupation, education level, income level, etc.

(2) Smoking history, drinking history, tea drinking history, preference for sweet food, hard food, vegetables and fruits and other behavioral risk factors.

(3) Psychological factors, whether the work pressure is big, whether there are negative life events in recent two years.

(4) Whether there is a history of diabetes, coronary heart disease, osteoporosis and other related diseases.

(5) Oral health behaviors and habits: daily brushing frequency, brushing time, brushing method, quality of toothbrush, brushing time, whether to use toothpick, whether to chew laterally, whether to have the habit of bruxism and biting at night.

(6) Whether regular oral examination is conducted for medical seeking behavior, and whether timely medical treatment is required after oral diseases

(7) Whether other dental cleaning expenses are self-paid and oral health knowledge level.

### 3.6. Quality Control of Investigation

All subjects signed informed consent. In the questionnaire survey, doctors must operate according to the unified plan and filling requirements. After the query and record of each object, the doctor should carry out a comprehensive examination on the content filled in. If you have any questions, please check again. If there are errors, they should be corrected in time, and the missing items should be supplemented in time. Nurses should check and accept each questionnaire and check the accuracy and completeness of the questionnaire from the night of the formal survey. If there is any mistake or omission, the doctor should be asked to correct it again the next day. Otherwise, the sample selection will be discarded. It can only be signed after careful examination.

### 3.7 Plaque Collection and Colony Extraction Process

The oral dentition is divided into four quadrants. At the deepest point of periodontal detection in each quadrant [13], the plaque was taken

- (1) The plaque was removed to avoid interference with the experiment.
- (2) After gargling, dry the sampling area and isolate with sterile cotton roll.
- (3) Plaque sampling: put 50 sterile paper tips on the sampling site in turn, take them out after standing for 30 seconds, put them into EP tube immediately and freeze them at  $-70\text{ }^{\circ}\text{C}$ .
- (4) On the workbench, open the EP tube, add  $100\mu\text{l}$  disinfectant water along the top edge of the paper, let the disinfection water flow from top to bottom of the EP pipe, and then close it.
- (5) The EP tube was placed in a dry water bath at  $200\text{ }^{\circ}\text{C}$  for 25 min.
- (6) The EP tube was removed and centrifuged at 23000 rpm at room temperature for 3 min. Without inhaling foreign bodies, the supernatant was inhaled into new EP tubules to obtain colony genomic DNA.

### 3.8 Treatment of Dental Plaque Specimens

The patient's name, gender, age, tooth position, mobility, probing depth and X-ray film were recorded. After the consent of the patients, the extracted teeth were placed in 5% paraformaldehyde fixed solution. After fixation for 72 hours, fresh teeth were extracted, numbered, washed with running water and immersed in 25% EDTA decalcification solution. The next day, the decalcification solution was replaced and decalcified at room temperature. When the teeth are soft enough to penetrate without resistance (about 5N), rinse the teeth with running water for about 24 hours, and then clean the residual decalcification solution, and then carry out the following operations:

- (1) Dehydration: rinse with tap water for 4 hours and then put it into automatic dehydrator for dehydration.
- (2) Tooth Division: due to the large size of human tooth tissue, there are some difficulties in the cutting process. Therefore, anterior teeth are divided into two parts: crown and root; posterior teeth are divided into crown, proximal root and distal root (palatal root).
- (2) Transparent: soak xylene I, II and III for 20min.
- (3) Paraffin immersion: paraffin I ( $100\text{ }^{\circ}\text{C}$ ) 20 min, paraffin II and paraffin III ( $100\text{ }^{\circ}\text{C}$ ) 30 min.
- (4) Embedding: paraffin embedded specimens. After the wax block is completely solidified, use a blade to remove the excessive paraffin around the tissue block.
- (5) Slicing: lecia slicing machine will blade and tissue block into a 5 degrees angle, along the long axis of tooth body evenly and slowly slice, the thickness is about  $8\mu\text{m}$ , each specimen takes 30 pieces.
- (6) Patch and baking: take out the wax with uniform thickness with small tweezers, put it into a



warm water bath (about 65 °C), flatten it, and then take it out on the glass slide. There are no bubbles and slippage on the wax. Baking slide: put the slide and wax slide in a 65 °C baking machine, bake at 65 °C for 3 hours, and refrigerate at 6 °C.

### 3.9 Shortcomings of the Experiment

This study is a case-control study, which only indicates the risk factors of the disease, does not consider the time series of exposure and outcome, and does not consider the causal relationship between exposure and outcome. Therefore, in order to determine whether there is a causal relationship between cognitive impairment and the occurrence and development of moderate to severe periodontitis, or whether periodontal pathogens and inflammatory mediators affect the occurrence and development of cognitive impairment. In addition, it is difficult to avoid selection bias when selecting research objects, and the sample size is relatively small, so it is difficult to avoid recall bias in the process of information collection. Therefore, in the follow-up study, it is necessary to further confirm the correlation between the two through large sample and multi factor experiments, and the biological mechanism of the relationship between the two needs to be further studied.

## 4. Results and Discussion

### 4.1. Comparison of Bi, PD and Al in Patients with Moderate and Severe Periodontitis before and After Operation

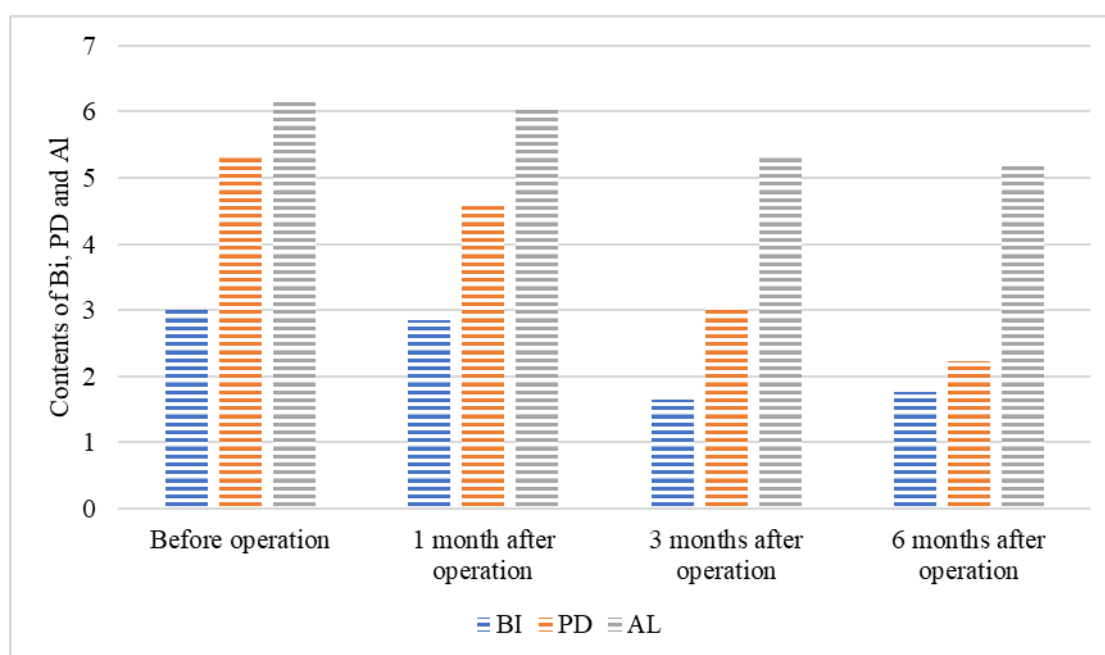


Figure 1. Changes of Bi, PD and Al before and 1-6 months after operation

Shown as Figure 1, the changes of Bi, PD and Al Contents in patients with moderate to severe periodontitis treated by microscope assisted periodontal flap surgery are different. The contents of Bi, PD and Al were improved in 1-3 months after operation. The content of PD decreased to the lowest at 6 months after operation, and the decrease range was the largest, while the content of Al had no obvious change compared with that before operation. The content of Bi decreased to the lowest in the third month after operation, and then began to rise slowly. The contents of Bi, PD and

AI in 1-3 months after operation were not recorded.

#### 4.2. Comparison of Periodontal Changes between the Two Groups before and After Treatment

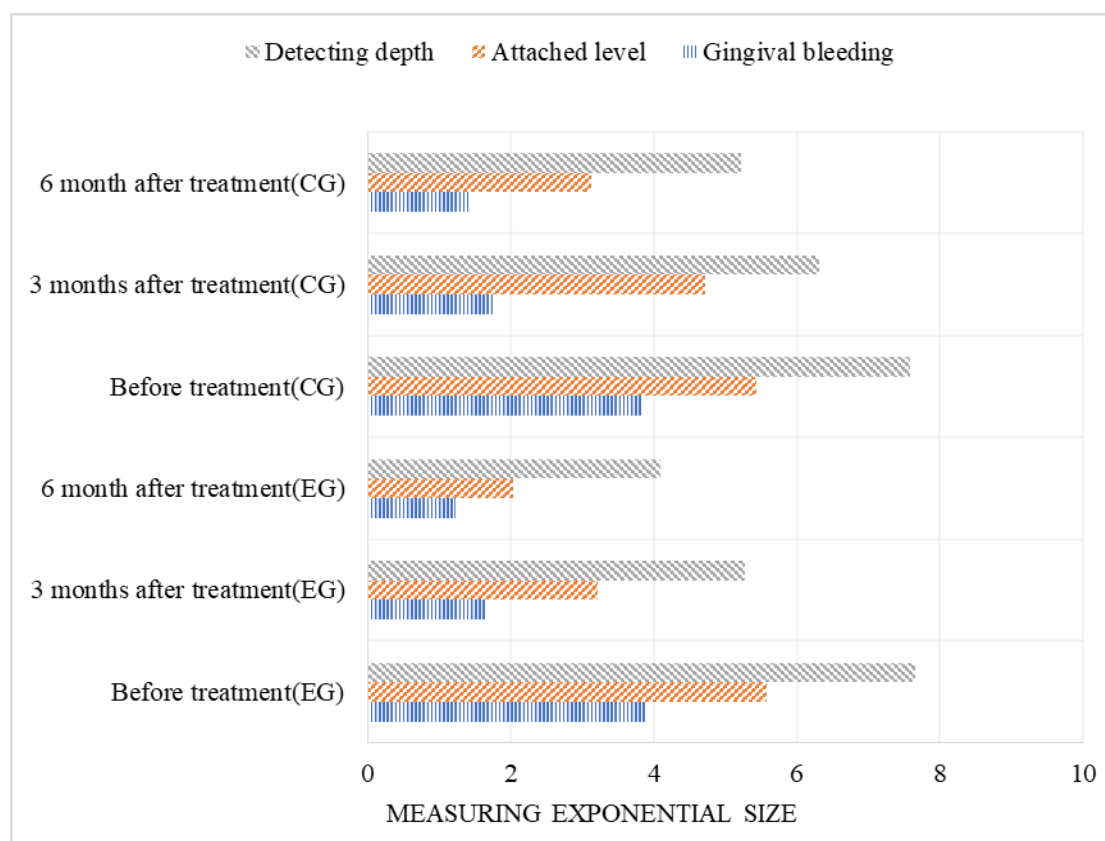


Figure 2. Comparison of periodontal changes between the two groups before and 3-6 months after treatment

Shown as Figure 2, there is no significant difference in the condition around the teeth detected before treatment. After 3-6 months of treatment, there was a great difference between the experimental group and the control group. The amount of gingival bleeding in the experimental group was much lower than that in the control group, and the attachment of teeth was much lower than that of the control group. The advantages of these two sets of data avoid patients using a longer length of the body for internal detection.

#### 4.3. Comparison of the Incidence of Gingivitis between the Two Groups before and After Treatment

Shown as Figure 3, the incidence of gingivitis before and after operation was analyzed and compared between the two groups. 24 cases in each group had inflammatory symptoms before treatment, and gradually improved after the recovery stage after operation. The incidence of gingivitis in both groups showed a decreasing trend, but the incidence of gingivitis in the experimental group was significantly lower than that in the control group. Until the sixth month, only four people had gingival inflammation symptoms, while the control group had a slight upward trend in the sixth month compared with the previous three months.

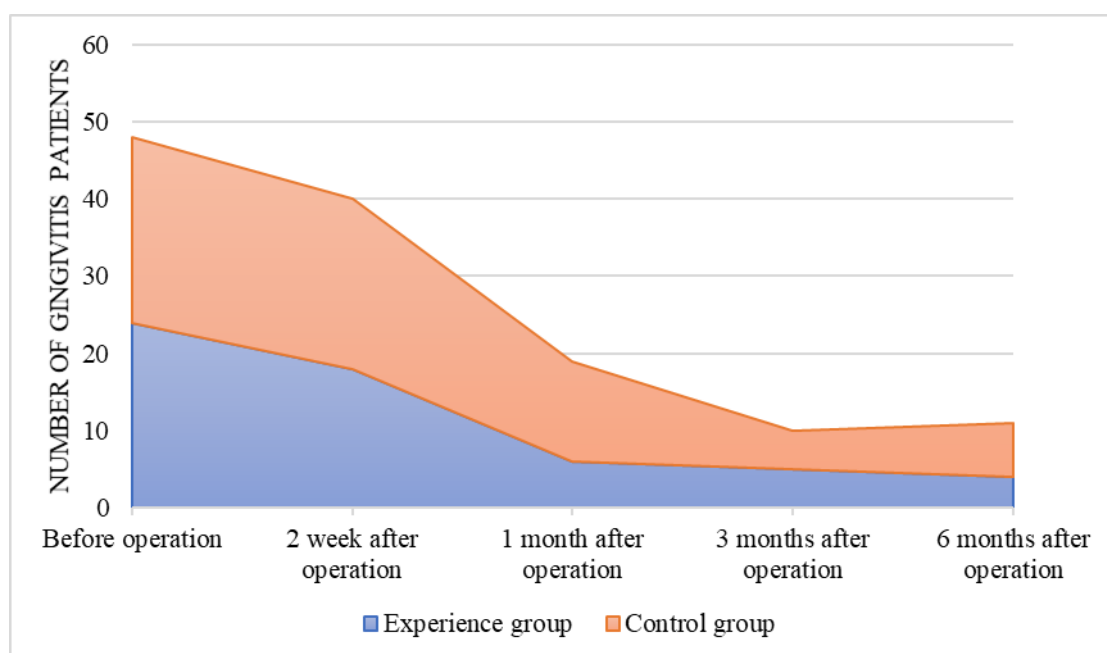


Figure 3. Comparison of the incidence of gingivitis between the two groups

#### 4.4. Comparison of Salivary Protease Activity around Gingiva between the Two Groups before and After Treatment

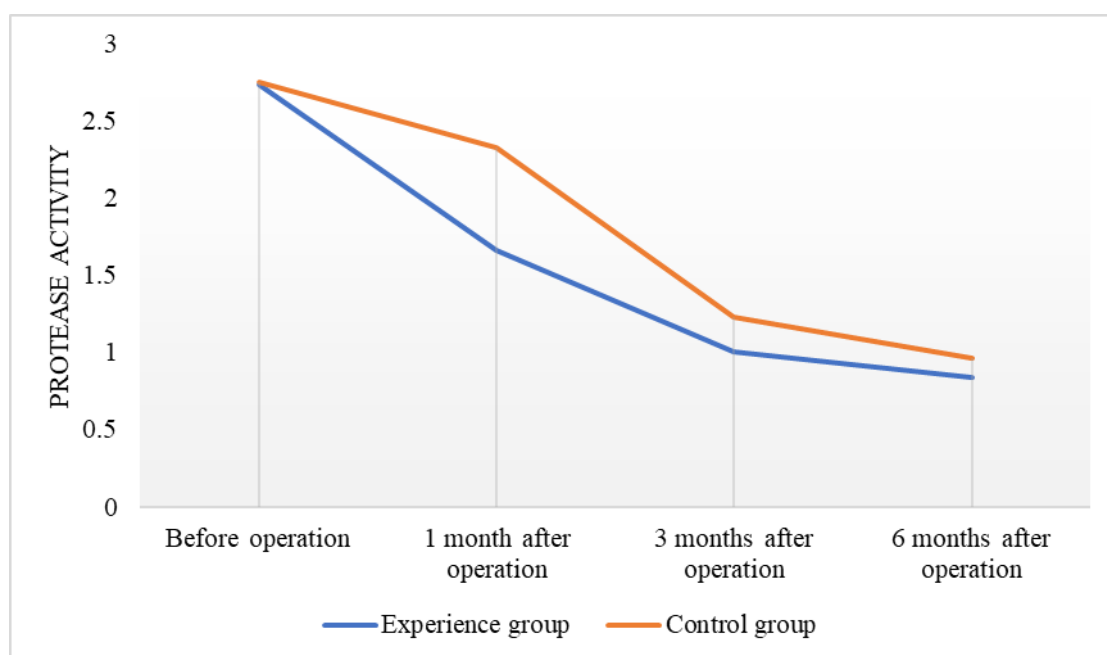


Figure 4. Comparison of periodontal salivary protease activity between the two groups before and 1-6 months after treatment

Shown as Figure 4, there was no significant difference between the two groups in the activity of salivary protease around the teeth before the experiment. The activity of salivary protease in the experimental group was lower than that in the control group from 1 month to 6 months after treatment.

## 5. Conclusion

Moderate and severe periodontitis requires strict removal of dental root tartar, calculus and other harmful dirt on the teeth, to reduce its persecution of the surrounding cell tissue, so that gingivitis does not occur again. It can also reduce the protease around the teeth and keep a clean periodontal environment for a long time. Microscopes can be used to observe the small cell tissue structure and enlarge the tooth structure tissue, so as to clearly observe the basic situation of moderate and severe periodontitis. In addition, the treatment of periodontal flap surgery is like a timely delivery of charcoal, which improves the treatment effect of moderate to severe periodontitis. Through the experimental analysis, due to the proper control of moderate and severe periodontitis, the changes of Bi, PD and AI Contents in patients with moderate and severe periodontitis treated by microscope assisted periodontal flap surgery were lower than those before operation, showing a good therapeutic effect; the amount of gingival bleeding in the experimental group after operation was much lower than that in the control group, and the attachment of teeth was also much lower than that of the control group. The results showed that the feasibility of this experiment with the aid of microscope was very high; the incidence of gingivitis in both groups was decreasing, but the incidence of gingivitis in the experimental group was significantly lower than that in the control group; the content of periodontal salivary protease in the experimental group was lower than that in the control group 6 months before and after treatment. It can be seen that the higher the protease concentration, the stronger the damage energy to the periodontal environment. Therefore, this experiment greatly reduced the regeneration of dental plaque in periodontal cells. Microscope assisted periodontal flap treatment is very good for the improvement of teeth, not only to solve the incidence of periodontitis, but also to avoid the growth of bacteria in the gingival root, effectively promote the recovery of moderate to severe periodontitis, which is worthy of clinical promotion.

## Funding

This article is not supported by any foundation.

## Data Availability

Data sharing is not applicable to this article as no new data were created or analysed in this study.

## Conflict of Interest

The author states that this article has no conflict of interest.

## References

- [1] Pinchback, J. S. , Taylor, B. A. , Gibbins, J. R. , & Hunter, N. . (2015). *Microvascular angiopathy in advanced periodontal disease. Journal of Pathology*, 179(2), 204-209.[https://doi.org/10.1002/\(SICI\)1096-9896\(199606\)179:2<204::AID-PATH552>3.0.CO;2-N](https://doi.org/10.1002/(SICI)1096-9896(199606)179:2<204::AID-PATH552>3.0.CO;2-N)
- [2] Philip D. Marsh, David A. Head, & Deirdre A. Devine. (2015). *Dental plaque as a biofilm and a microbial community—implications for treatment. BMC Oral Health*, 57(4), 185-191.<https://doi.org/10.1016/j.job.2015.08.002>
- [3] Chang, J. F. , Yeh, J. C. , Chiu, Y. L. , Liou, J. C. , & Tung, T. H. . (2017). *Periodontal pocket depth, hyperglycemia, and progression of chronic kidney disease: a population-based*

- longitudinal study. *American Journal of Medicine*, 130(1), 61-69. <https://doi.org/10.1016/j.amjmed.2016.08.024>
- [4] Jae-Hong, L. , Jung-Kyu, C. , Sang-Hyun, K. , Kyung-Hyun, C. , Young-Taek, K. , & Seong-Ho, C. , et al. (2017). Association between periodontal flap surgery for periodontitis and vasculogenic erectile dysfunction in koreans. *Journal of Periodontal & Implant ence*, 47(2), 96. <https://doi.org/10.5051/jpis.2017.47.2.96>
- [5] Thierry Lefèvre MD, Louvard, Y. , Marie Xlaude Morice, Dumas, P. , & Jean =ranois Pi échaud. (2015). Stenting of bifurcation lesions: classification, treatments, and results. *Catheter Cardiovasc Interv*, 49(3), 274-283. [https://doi.org/10.1002/\(SICI\)1522-726X\(200003\)49:3<274::AID-CCD11>3.0.CO;2-N](https://doi.org/10.1002/(SICI)1522-726X(200003)49:3<274::AID-CCD11>3.0.CO;2-N)
- [6] Giorgi, C. , Eisenberg, H. , Costi, G. , Gallo, E. , & Casolino, D. S. . (2015). Robot-assisted microscope for neurosurgery. *Journal of Image Guided Surgery*, 1(3), 158-163. [https://doi.org/10.1002/\(SICI\)1522-712X\(1995\)1:3<158::AID-IGS5>3.0.CO;2-9](https://doi.org/10.1002/(SICI)1522-712X(1995)1:3<158::AID-IGS5>3.0.CO;2-9)
- [7] Pinchback, J. S. , Taylor, B. A. , Gibbins, J. R. , & Hunter, N. . (2015). Microvascular angiopathy in advanced periodontal disease. *Journal of Pathology*, 179(2), 204-209. [https://doi.org/10.1002/\(SICI\)1096-9896\(199606\)179:2<204::AID-PATH552>3.0.CO;2-N](https://doi.org/10.1002/(SICI)1096-9896(199606)179:2<204::AID-PATH552>3.0.CO;2-N)
- [8] Chapple, C. C. , Srivastava, M. , & Hunter, N. . (2015). Failure of macrophage activation in destructive periodontal disease. *Journal of Pathology*, 186(3), 281-286. [https://doi.org/10.1002/\(SICI\)1096-9896\(1998110\)186:3<281::AID-PATH200>3.0.CO;2-7](https://doi.org/10.1002/(SICI)1096-9896(1998110)186:3<281::AID-PATH200>3.0.CO;2-7)
- [9] P.C. White, I.J. Chicca, P.R. Cooper, M.R. Milward, & I.L.C. Chapple. (2016). Neutrophil extracellular traps in periodontitis. *Journal of Dental Research*, 95(1), 26-34. <https://doi.org/10.1177/0022034515609097>
- [10] Janda, M. S. , Mattheos, N. , Nattestad, A. , Wagner, A. , & R Attström. (2015). Simulation of patient encounters using a virtual patient in periodontology instruction of dental students: design, usability, and learning effect in history-taking skills. *European Journal of Dental Education*, 8(3), 111-119. <https://doi.org/10.1111/j.1600-0579.2004.00339.x>
- [11] Anna Mosiołek, Gierus, J. , Koweszko, T. , Borkowska, A. , & Szulc, A. . (2017). The cognitive screening scale for schizophrenia (csss) – part 1: development and structure of the scale. *Psychiatria polska*, 52(2), 1-16. <https://doi.org/10.12740/PP/OnlineFirst/64831>
- [12] Oh, H. , Hirano, J. , Takai, H. , & Ogata, Y. . (2015). Effects of initial periodontal therapy on interleukin-1 $\beta$  level in gingival crevicular fluid and clinical periodontal parameters. *Journal of Oral ence*, 57(2), 67-71. <https://doi.org/10.2334/josnusd.57.67>
- [13] Gaertig, C. , Niemann, K. , Berthold, J. , Giel, L. , Leitschuh, N. , & Boehm, C. , et al. (2015). Development of a point-of-care-device for fast detection of periodontal pathogens. *Bmc Oral Health*, 15(1), 165. <https://doi.org/10.1186/s12903-015-0155-y>