

## ***Rehabilitation Nursing of Patients with Renal Failure under Microscope Underwent Cephalic Vein Radial Artery Fistula***

**Song Yan\***

*Guizhou Minzu University, Guiyang, China*

*\*corresponding author*

**Keywords:** Renal Failure, Arteriovenous Fistula, Rehabilitation Nursing, Vascular Conditions, Microscope Observation

**Abstract:** Studying the regular monitoring of postoperative complication diameter shape and accessibility of the path can avoid premature use of the path, and can promptly detect postoperative complications and fistula use, which can help the clinic to take corresponding measures in time. This article mainly studies the rehabilitation nursing of cephalic vein radial artery fistula angioplasty in patients with renal failure. In this paper, patients who have established autologous arteriovenous fistula are the research object. Statistics of 324 patients with primary disease, age, preoperative vascular color Doppler ultrasound, surgical site (wrist, middle forearm, and high position near elbow fossa), complications within 2 months after surgery (including internal fistula occlusion) and postoperative Fistula dysfunction within 2 months. SPSS-19.0 statistical software was used for analysis. Analyze the relationship between the success rate of surgery, the occurrence of postoperative clinical complications and the etiology, age, vascular condition, surgical site, method and postoperative treatment of the patient. This study found that 19 cases (6.2%) of internal fistula dysfunction were evaluated 2 months after surgery. The incidence of swollen hand syndrome and heart failure near the elbow fossa and middle forearm was higher than that of wrist fistula ( $P < 0.05$ ). Patients with internal fistula and simultaneous resection of aneurysm had a high infection rate of internal fistula ( $P < 0.05$ ). The intraoperative secondary surgical anastomosis was related to vascular conditions ( $P < 0.05$ ) and surgical methods. The results of the study show that the postoperative ultrasound assessment of the head vein flow and diameter of autogenous arteriovenous fistula meets the requirements of dialysis, which can help to detect early early use of arteriovenous fistula and diagnose and treat it as soon as possible, and strive for reuse.

## 1. Introduction

Chronic renal failure refers to a syndrome composed of a decrease in glomerular filtration rate caused by chronic kidney disease and other renal impairment, and the resulting metabolic disorders and clinical symptoms. Cardiovascular disease is the most common and serious complication of chronic renal failure and the leading cause of death in such patients. The main cause of death in patients with chronic renal failure who have or have not undergone dialysis is cardiovascular disease, which occurs in patients with end-stage renal disease. The risk of cardiovascular disease is 20 times that of the control group of the same age. Many patients with chronic renal failure have died of cardiovascular complications before reaching the dialysis standard.

Early cardiovascular disease may have no clinical symptoms, and the age of occurrence is significantly lower than normal people, and once formed, it will progress rapidly, so early detection of cardiovascular disease and symptomatic treatment are important for improving the prognosis and prolonging survival of patients with chronic renal failure. To explore the relationship between the success rate of surgery, the occurrence of postoperative complications and the etiology, age, vascular conditions, surgical site, method and postoperative management of patients with autologous arteriovenous fistula. In order to provide scientific guidance for improving the success rate of autogenous arteriovenous fistula surgery and reducing the incidence of complications.

Arteriovenous fistula (AVF) is the preferred hemodialysis vascular access, but its failure rate is high and the accompanying incidence is high. Kang described the murine AVF model. His model summarizes two salient features of AVF in hemodialysis, namely the anastomosis of the terminal vein and the lateral artery to form AVF and the presence of chronic kidney disease (CKD). CKD reduced the blood flow of AVF, which was observed as early as three days after AVF production, and increased neointimal hyperplasia, venous wall thickness, thrombosis and vascular disease gene expression in AVF. These adverse effects of CKD cannot be attributed to pre-existing changes in blood pressure or vascular reactivity in this CKD model. In addition to vascular disease genes, CKD also induces potential vascular protection genes in AVF, such as heme oxygenase-1 (HO-1) and HO-2. In order to determine whether the previous upregulation of HO-1 can be protected in this model, he upregulated HO-1 through the transmission of adeno-associated virus genes, thereby achieving obvious venous induction of HO-1 protein and HO activity. This upregulation of HO-1 improves AVF blood flow and reduces AVF vein wall thickness [1]. The issues considered by his method are not particularly comprehensive. Due to the lower complication rate compared with central venous catheters (CVC), arteriovenous fistula (AVF) is now the preferred hemodialysis route. The recommended range for first-time intubation is 6 to 12 weeks, which may result in a temporary or permanent preference for CVC before waiting for the newly created AVF to mature. Almási-Sperling assessed the impact of AVF's first intubation on the primary (PP) and secondary (SP) patency rates of children's hemodialysis (HD). He studied 42 pediatric patients with a median age of 14 years (7-17 years). At the time of surgical AVF, 21 patients (end-stage renal disease) were still receiving HD treatment through CVC or peritoneal catheters, while 21 were still in the preemptive state, and HD is expected to be triggered within a few weeks. Between February 1993 and May 2014, all patients received AVF by the same experienced surgeon. Primary failure (PF) is defined as the inability to use AVF even if it is immature or occlusive within 4 weeks of creation [2]. His research is insufficiently targeted and cannot be applied to individual special problems. The aim vascular access in hemodialysis is essential for effective treatment. Lee evaluated the outcome of arteriovenous fistulas (AVF) in hemodialysis patients, the impact of preoperative venous imaging, and predictors of the successful maturation of AVF in their centers. He retrospectively collected data on patients with end-stage renal disease (ESRD) who underwent hemodialysis in our center from January 2010 to December 2012. Collect demographic characteristics, comorbidities,

perioperative details, and follow-up patients until January 1, 2014. He believes that most hemodialysis patients can successfully form arteriovenous fistulas. If conventional physical examination can be performed only by venous examination, conventional venous mapping is not required, and the size of veins less than 2mm and low AVF maturation rate on ultrasound examination Irrelevant[3]. His method lacks the possibility of responding to emergencies in practical applications.

Safety management is a necessary condition to ensure the safety of patients, and it is a key link to avoid nursing defects and improve nursing level. As a hospital nurse, it is particularly important to implement safety management for patients. To apply safety management to the care management of patients with cardiovascular disease, we should start from improving the safety management system and improving the professional quality of nursing staff. Through the key links, key periods, key personnel and The management of ward facilities has created a safe atmosphere, and also increased the importance of nursing staff on safety, thus preventing the occurrence of error accidents and further ensuring the safety of patients. Each hospital should establish a comprehensive nursing quality management system and continuously improve the potential problems in each link in order to fundamentally continuously improve the quality of nursing, eliminate the hidden dangers of nursing, provide safe care for patients, and then eliminate nursing errors and nursing disputes happened.

## **2. Renal Failure and Mature Mechanism of Arteriovenous Fistula**

### **2.1. Renal Failure**

With the development of disease, the accumulation of toxic substances and the increase of water and sodium retention in patients with chronic renal failure increase the permeability of alveolar capillaries and increase the permeability of the pulmonary vessels[4], leading to the transfer of fluid from lung to interstitial lung, resulting in the occurrence of pulmonary edema, affecting the ventilation function and increasing the distance of alveolar capillary membrane dispersion[5]. The airway is compressed, which makes the airway close in advance, and changes similar to obstructive ventilation dysfunction [6].

Malnutrition is common in patients with chronic renal failure due to insufficient erythropoietin secretion and metabolic restriction or strict diet control[7]. Renal anemia is the most common clinical complication in patients with chronic renal failure, and anemia has a certain impact on lung diffusion function[8]. Anemia is one of the important reasons for the decrease of lung diffusion function. It proposed that for every LG / L decrease in hemoglobin, the predicted value of carbon monoxide dispersion will decrease by 7% [9]. The hemoglobin of patients with chronic renal failure is lower than that of normal people, and oxygen is mainly combined with hemoglobin in the blood. The relative lack of hemoglobin will affect the diffusion capacity of oxygen. Dystrophic patients with chronic renal failure may have skeletal muscle dysfunction, which may lead to respiratory muscle function damage. Because lung function is closely related to the body muscle volume and strength, it can cause lung function damage [10]. Inflammatory factors produced in the body's inflammatory state can inhibit appetite, cause gastrointestinal function changes, affect glucose metabolism and insulin resistance, thus affecting nutritional status. When the nutritional status is not good, the muscle mass of human body decreases correspondingly, and the function of skeletal muscle can not function normally, which causes respiratory muscle to be affected, and finally leads to the damage of human ventilation function. At the same time, some studies have shown that the body's inflammatory state decreases, reduces iron absorption, increases body iron consumption, and even inhibits the production of red blood cells, thus playing a role in resisting the production of erythropoietin and aggravating anemia [11].

## 2.2. Atherosclerosis

The etiology of chronic renal failure is complex, and the causes can be divided into internal and external causes. Internal causes are mainly responsible for the prolonged disease, which consumes Qi and blood Yin and Yang, leads to deficiency of Qi and blood Yin and Yang, and dysfunction of viscera; external causes are mainly caused by improper diet, invasion of external pathogens, overwork and treatment failure and mistreatment of diseases. The pathogenesis of the disease is mixed with deficiency and excess, yin and yang are damaged, and the deficiency of positive and pathogenic excess always runs through the disease. The key pathogenesis of chronic renal failure is spleen and kidney deficiency. Atherosclerosis is a chronic, progressive pathological process that occurs in large and middle arteries. The characteristic of atherosclerosis is that the lesions of the affected artery start from the intima, and there are multiple lesions coexisting, including local accumulation of lipids and extracellular matrix, smooth muscle cells, fibrous tissue hyperplasia and calcification to form plaques, and With the gradual degeneration of the middle layer of the artery, secondary lesions still have intraplaque hemorrhage, plaque rupture, aneurysm formation and local thrombosis, anatomical stenosis and secondary thrombosis, resulting in a significant reduction in effective blood flow in the blood vessel It leads to ischemia or infarction, which is especially important for important organs and tissues such as heart and brain. The etiology and pathogenic mechanism of this disease have not been fully determined. Extensive and in-depth research on common atherosclerosis has shown that this disease is a multi-cause disease, that is, multiple factors act on different links. The traditional view is that The occurrence of atherosclerosis, and genetics[12], hyperhomocysteinemia, metabolic syndrome (obesity, hypertension, hyperlipidemia, diabetes, etc.), smoking, mental stress, environmental factors and viral infections, chlamydia infections, etc. related. Clinical observation and gross anatomy show that the focal lesions of AS have high selectivity, that is, atherosclerosis always occurs in the openings, bends, bifurcations, and stenosis of the arteries. The physiologically prevalent sites of human AS: coronary arteries : The left anterior descending branch and the circumflex branch are mainly due to its complicated geometric structure, degree of curvature, and repeated mechanical compression of cardiac contraction and relaxation; the main branch of the aortic arch: the carotid artery is the main branch, and the abdominal aortic branch (abdominal artery , Superior mesenteric artery, inferior artery, renal artery), distal abdominal aorta and internal iliac artery branch, terminal abdominal aorta branch, and this atherosclerosis distribution characteristics are difficult to explain with the traditional risk factors mentioned above. However, these high-incidence arterial parts often change from normal laminar flow to complex flow phenomena due to bending, bifurcation, and opening, such as flow separation, backflow, turbulence, and slow flow velocity. The high selectivity of focal lesions in AS may be It is related to the complex flow phenomenon of blood flow in these parts, such as the laminar flow of blood flow being broken and oscillating. Recent studies by many foreign scholars have confirmed that the change in vascular stress caused by abnormal blood flow is the preferred factor for the formation of AS[13]. The blood is in close contact with the blood vessel wall, and the flow of blood will continuously produce various forces on the blood vessel wall, including shear force, peripheral stress and compressive stress, etc., where the blood flow shear force is considered to be atherosclerotic plaque and easy The most important mechanical factor for the formation of damaged plaques; studies have confirmed that the effect of blood flow on blood vessels is an important extracellular signal for the growth of blood vessel walls, and plays a key role in regulating the changes of blood vessel structure and function[14].

## 2.3. Biological Mechanism of Arteriovenous Fistula Maturation Failure

With the production of arteriovenous fistula, the laminar blood flow increased rapidly, and

caused the increase of NO level. In addition to direct NO-induced relaxation enhancement and inhibition of smooth muscle cell migration and proliferation, the released NO and oxygen free radicals generate peroxynitroso, thereby stimulating MMP.2 and MMP.9. Elevated MMP.2 and MMP.9 specifically destroy the arterial elastin fibers, resulting in a more permanent outer layer remodeling. In fact, more than 50% of arteriovenous fistulas fail to mature. Radiologically, the failure of internal fistula maturation is characterized by stenosis around the anastomosis. Biologically, a large number of neointimal hyperplasias with the absence of outer layer remodeling (expansion) or the presence of inner layer remodeling (vasoconstriction) cause stenosis. Surgical procedures, dissection of the adventitia of the arteries, direct damage to the suture, oxidative stress and baseline improvement in inflammatory response, the most important may be severe hemodialysis shear stress (non-laminar blood flow with blood flow separation and oscillating shear stress) These upstream stimuli are considered to be the cause of neointimal hyperplasia and lack of expansion.

The reduction of hemodialysis shear stress leads to endothelial activation, especially through NO release. Low NO levels will lead to neonatal endothelial hyperplasia (because NO blocks smooth muscle cell migration and hyperplasia) and dilation loss (because NO is a powerful vasodilator), and eventually cause anastomotic stenosis and fistula maturation failure. Indirectly supporting recent research from our laboratory, we found that the fistula in the curved structure increased the flow and diameter compared to the linear structure, which shows that the difference in hemodynamics may lead to different clinical endpoints, such as flow and diameter.

## 2.4. Microscope Image Fusion Gradient

The purpose of using the gradient function is to make the color transition gradually, avoiding the blur and obvious border of the image. The main idea of this method is: the overlapping part gradually transitions from the previous image to the second image, that is, the pixel values of the image overlapping area are added by a certain weight to synthesize a new image. At present, the method of linear transition in overlapping regions is mostly used. The specific method implemented by taking horizontal stitching as an example assumes that the image overlap area is L. Suppose the coordinates of the latter image are (0, Y). Take the weight of the previous image as  $\phi[y]$ , and y is

the column value in the previous image. Then  $\phi[y] = \frac{(y-Y)}{L}$ , the intensity of the pixel in the y-th column in the overlapping area is:

$$I[y] = I_x[y] \times \phi[y] + I_y[y] \times (1 - \phi[y]) \quad (1)$$

The linear transition algorithm is simple and the transition is natural. However, for large-scale image stitching, there is a phenomenon of misalignment between images, and the overlapping relationship between images is also more complicated, so if only a simple linear transition is used, it cannot meet the requirements. Therefore, in the process of large-scale image stitching, this paper uses the feather weight function and the nearest image center weight function for image fusion.

### (1) Feather weight function

The weighting function is related to the input image, and attenuates from the center of the image until the image boundary is zero. According to the distribution weight of the image, the values of the three pixels R, G, and B corresponding to the three channels in the image after the synthesis are calculated respectively in the image. The function is shown in equation (2):

$$f(x, y) = \left\{ 1 - \left[ \frac{(x - \frac{w}{2})}{\frac{w}{2}} \right]^2 \right\} \left\{ 1 - \left[ \frac{(y - \frac{h}{2})}{\frac{h}{2}} \right]^2 \right\} \quad (2)$$

Among them, w and h represent the width and height of the image, respectively.

(2) Weight function of the nearest image center

When using this weight function, the sampling position relative to the center of the image must also be calculated. The specific mathematical expression is as formula (3):

$$f(x, y) = 1 - \sqrt{1 - \left(x - \frac{w}{2}\right)^2 + \left(y - \frac{h}{2}\right)^2} / \sqrt{x^2 + y^2} \quad (3)$$

### 3. Experimental Design of Intraarterial Bag Surgery

#### 3.1. General Information

A total of 324 patients with end-stage renal disease in the Department of Nephrology and Vascular Surgery of a hospital were selected, all of whom were the first patients undergoing forearm radial artery-cephalic autogenous arteriovenous fistula. There were 178 males and 143 females, aged 18-80 years. The primary causes of the patient were 81 cases of diabetic nephropathy, 83 cases of hypertensive nephropathy, 107 cases of glomerulonephritis, 38 cases of polycystic kidney disease, and 15 cases of renal vascular stenosis.

#### 3.2. Selection Criteria

All were the first autologous arteriovenous fistula surgery for end-stage renal disease. The operating staff are all in the same medical group of vascular surgery. The surgical site is one of the bilateral forearms, usually the patient's non-habitual limb. Separate the radial artery and cephalic vein, and end-to-end anastomosis of the cephalic vein and radial artery, using continuous suture, the anastomotic diameter is about 6mm. Postoperative physical examination showed that the anastomotic tremor was good, and there was no abnormal enhancement, weakening, or disappearance. The veins at the end of the fistula were straight, superficial, and easy to puncture. The blood vessel wall of the fistula was flexible and could touch the tremor. There was no increase or decrease or disappearance of pulsation. Postoperative regular follow-up of color Doppler ultrasound technique. Color Doppler ultrasound examination of arteriovenous fistula is the same machine and the same operator.

#### 3.3. Experimental Design

Conventional disinfecting drapes, local anesthesia with 1% lidocaine, take a length of about 5 cm along the distal end of the left forearm and the radial artery, cut through the skin, subcutaneous, and subcutaneous tissue for exploration, look for the cephalic vein, see the diameter of the cephalic vein It is 2.1mm, and the silicone tube is suspended for standby. Explore and cut the radial arteriovenous vascular sheath and separate the radial arteriovenous vein. The radial artery diameter is about 3.5mm and the pulse is good. There is no obvious arteriosclerotic plaque. The free radial artery is 3cm. The silicone tube is suspended for use. Cephalic-radial artery end-to-side anastomosis was performed. The proximal end of the cephalic vein was blocked with forceps, the cephalic vein was cut off, and the distal silk thread was ligated. Heparin saline was injected into the proximal end of the cephalic vein to dilate the cephalic vein, and the venous vein was unobstructed. The proximal end was trimmed into the shape of a snake head to facilitate anastomosis, and the diameter was about 10mm. Intravenous injection of 15 mg heparin sodium, the radial artery was blocked at the proximal end and the distal end, and the radial artery was cut with a sharp knife. The incision of the microsurgical scissors was extended by about 10 mm to match the broken end of the cephalic vein. The cephalic vein makes an angle of about 60 degrees with the radial artery. Double needle 6-0

PROLENE vascular suture continuous small margin end-to-side anastomosis of the cephalic vein near the heart and radial artery, pay attention to prevent the vascular wall adventitia, narrowing, etc., remove the artery blockage, see the cephalic vein pulsation is good, tremor The feeling is not obvious. The distal radial artery is well pulsed. Ulnar artery pulse is good. The finger is ruddy, the capillary filling is good, the wound is completely hemostasis and the subcutaneous and skin are sutured, and the incision is covered with sterile gauze. The operation is finished.

### 3.4. Statistical Methods

Use SPSS19.0 software for statistics. All measured data are expressed as mean±standard deviation ( $\bar{x} \pm s$ ). Quantitative data are compared between the anterior wall and posterior wall IMT of the internal fistula group and the anterior wall and posterior wall IMT of the control group using paired t test, and the internal In the fistula group, the radial wall posterior wall  $V_m$ ,  $D$ ,  $\tau_m$  and the control group radial artery posterior wall  $V_m$ ,  $D$ ,  $\tau_m$  were compared by independent sample t test, and Spearman rank correlation analysis was used between  $\tau_m$  and IMT data. Setting  $P < 0.05$  is considered statistically significant.

## 4. Analysis of Rehabilitation Nursing for Intra-Arterial Bag-Plasty Operation

### 4.1. Incidence of Complications in Patients with AVF Application for 1 Year

Table 1. Number of failures in experimental group and control group

	Failure	Good function	Power loss
Experimental group	12	156	7.7%
Control group	3	153	2.0%

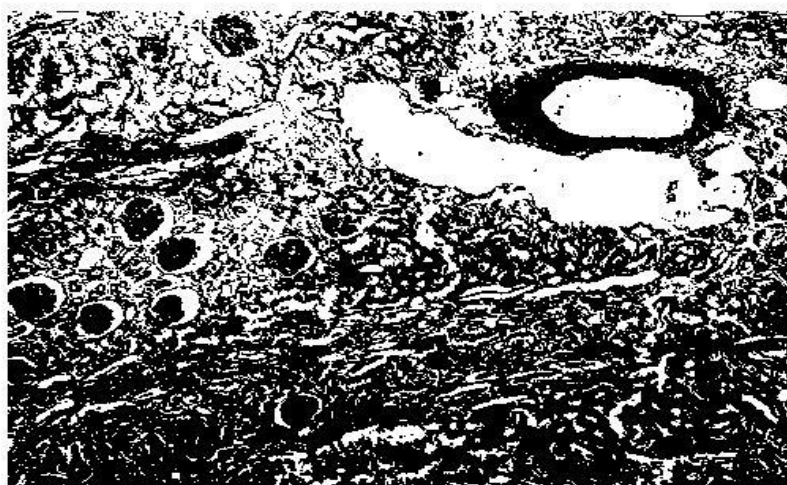


Figure 1. Swelling of kidney tubular epithelial cells

As shown in Table 1 and Figure 1, of the 168 hemodialysis patients in the experimental group, 12 patients had arteriovenous fistula failure due to cephalic thrombosis; 8 loyal people had increased venous pressure during dialysis, and blood reflux was difficult. Central venography showed tortuosity of the superior cephalic vein, and no obvious stenosis was seen. After reselecting

the puncture site, the venous pressure was normal during dialysis; 5 cases of venous tumor-like dilation at the puncture site. Of the 156 dialysis patients in the control group, 5 patients had an arteriovenous fistula failure. Color Doppler ultrasound showed cephalic vein thrombosis. 3 patients had swollen upper extremities on the side of the fistula during dialysis to the elbow joint. Color ultrasound showed the elbow joint A transvenous reflux can be seen at the distal end. There was no significant difference in the incidence of complications between the two groups ( $P>0.05$ ).

It takes at least 4 weeks for the fistula to mature. If the vein is not fully dilated at 8 weeks after the operation, the blood flow is 600 ml/min, and the dialysis blood flow is insufficient (except for the technical factors of the puncture), the fistula is not mature or hypoplasia. Three months after surgery is not mature, it is considered that the fistula operation failed. Comprehensive clinical symptoms and laboratory indicators were used to evaluate the efficacy of all patients. Fistula flow  $>600\text{ml/min}$  within 4 weeks after operation was defined as marked effect; fistula flow within 6 weeks after operation was defined as effective; 600ml/min was defined as effective; within 6 weeks after operation Fistula flow  $<600\text{ml/min}$  is defined as invalid. The results showed that as shown in Table 2 and Figure 2, the control group treated 156 cases, markedly effective in 39 cases (25.0%), effective in 79 cases (50.6%), the total effective rate was 75.6%, and 38 cases (24.4%) were ineffective; Among the 164 patients in the treatment group, 96 were effective (58.5%), 66 were effective (40.2%), and the total effective rate was 98.7%. The effect of the Chinese medicine bubble hands group is better than that of the warm water bubble hands group. The two groups are statistically significant ( $p > 0.05$ ).

Table 2. Comparison of treatment effect between the two groups

Group	Marked effect	Effective	Always effective	Invalid
Chinese medicine bubble hands group(n=164)	96(58.5%)	66(40.2%)	162(98.70%)	2(1.3%)
Warm water bubble hands group (n=156)	39(25.0%)	79(50.6%)	118(75.6%)	38(24.4%)

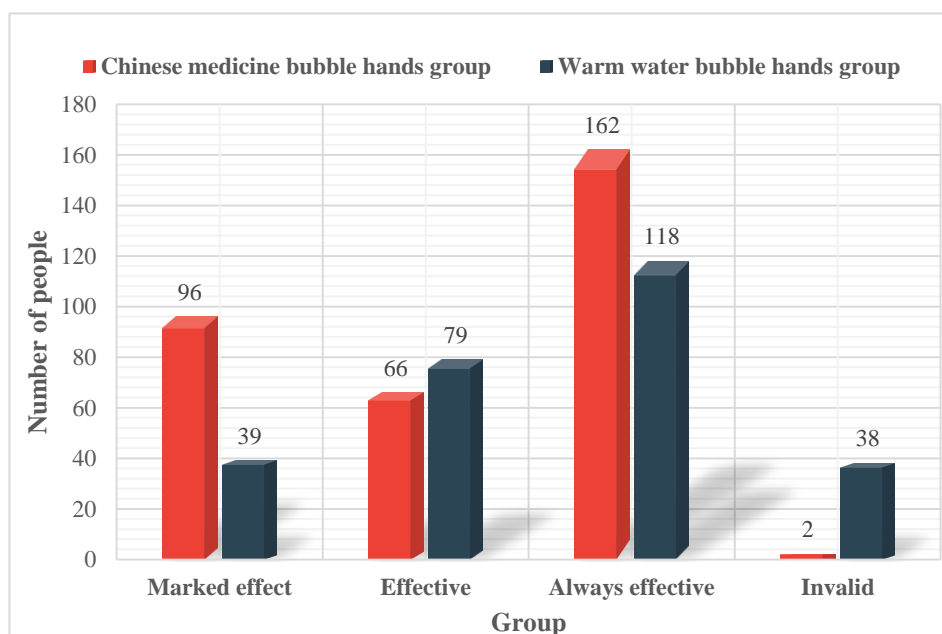


Figure 2. Comparison of treatment effects between the two groups



## 4.2. Safety Observation and Analysis

Adhere to safety monitoring during clinical observation, and faithfully record any adverse events complained by the patient or observed by the physician, including any adverse medical events that occurred in this clinical observation during the period from the patient's enrollment start to the end of the observation, regardless of this Whether the event has a direct causal relationship with the treatment plan. The content of the record also includes its severity, duration, treatment process, outcome, etc., and on the basis of comprehensive consideration of comorbidities and co-administration of drugs, evaluate whether it is relevant to the treatment of traditional Chinese medicine. The indicators or symptoms for safety monitoring are the presence or absence of drug allergies, skin color, skin scalds, skin infections in the fistula, ischemia of the terminal fingers, hand dysfunction and tremor of the fistula; laboratory indicators are blood flow of the fistula, Pipe size.

In this study, all patients did not have abnormal events such as internal fistula function, skin allergies, infections, etc. The treatment process was smooth and no discomfort such as fistula hand dysfunction occurred. Both groups of patients had improved internal fistula tremor, blood flow and internal fistula diameter after using traditional Chinese medicine or warm blisters. In the treatment group, 3 patients (7.2%) had mild skin burns during the first week of soaking the hands, and the condition was relieved after suspending the Chinese medicine soaking hands and topical burn ointment. The Chinese medicinal foam group showed brownish-yellow and brown skin. Considering that it was caused by the staining of Chinese herbal medicine decoction, the patient had no obvious discomfort, which mainly affected the appearance. The patient was still acceptable, so no adverse events were handled. In this comprehensive intervention treatment plan, it is a traditional Chinese medicine external treatment method, which is safe and peaceful, and has no damage to tissues and organs. After training and education, patients can master the operation process, so as to avoid potential risks such as skin scald, infection and affecting the function of ostomy hand. However, from this study, there are still 3 patients with minor skin burns. Considering that the patient is an elderly diabetic patient, there is abnormal neurological function. Therefore, in future experiments or treatments, the diabetic patients must pay attention to the water temperature to prevent similar events. Adverse reaction observation record are show in Table 3.

*Table 3. Adverse reaction observation record*

Adverse events	Chinese medicine soaking hand group	Warm water bubble hands group
Allergy	0	0
Skin infections	0	0
Skin burns	3	0
Finger ischemia	0	0
Hand dysfunction	0	0

As shown in Figure 3, 28 patients in the case group measured SV ( $58.5 \pm 17.76$ ) ml 1 week before surgery, and ( $58.5 \pm 1.32$ ) ml measured 8 weeks after surgery.  $t=1$ , indicating no statistical significance, including 16 male patients ( $63.31 \pm 16.37$  VS  $62.38 \pm 15.16$ ,  $P=0.39$ ) and 12 female patients ( $52.08 \pm 18.17$  VS  $52.33 \pm 17.00$ ,  $P=0.05$ ). There was no statistically significant difference in SV values before and after.

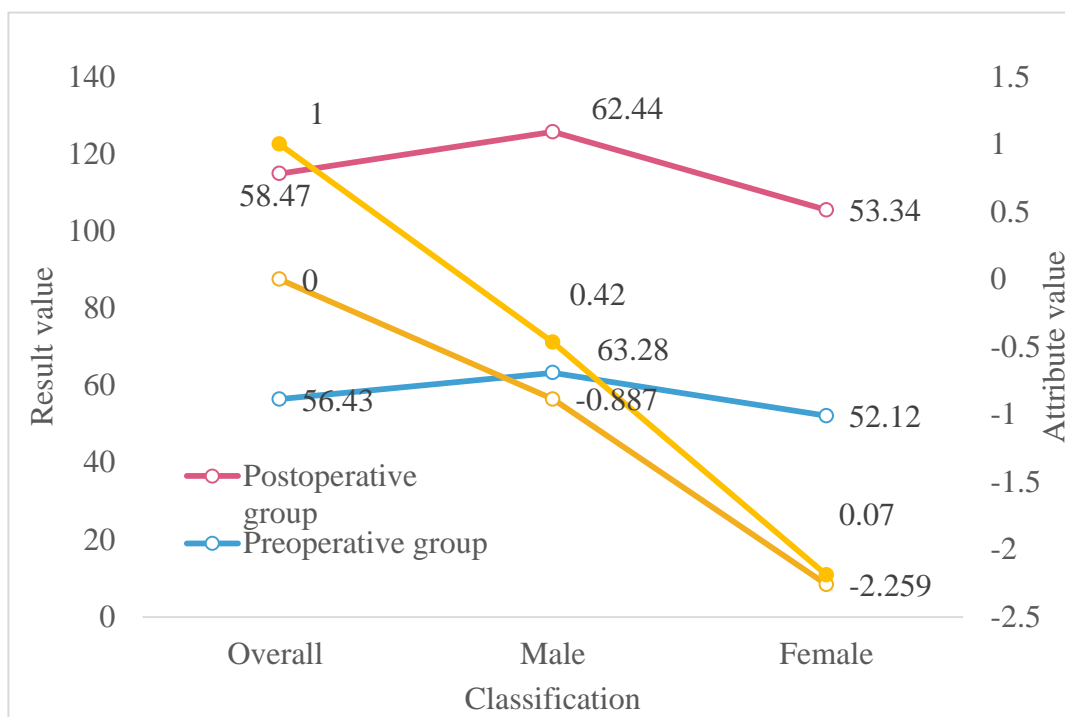


Figure 3. Comparison of SV results of male and female patients before and after operation

### 4.3. Correlation Analysis of Renal Failure and Lung Function

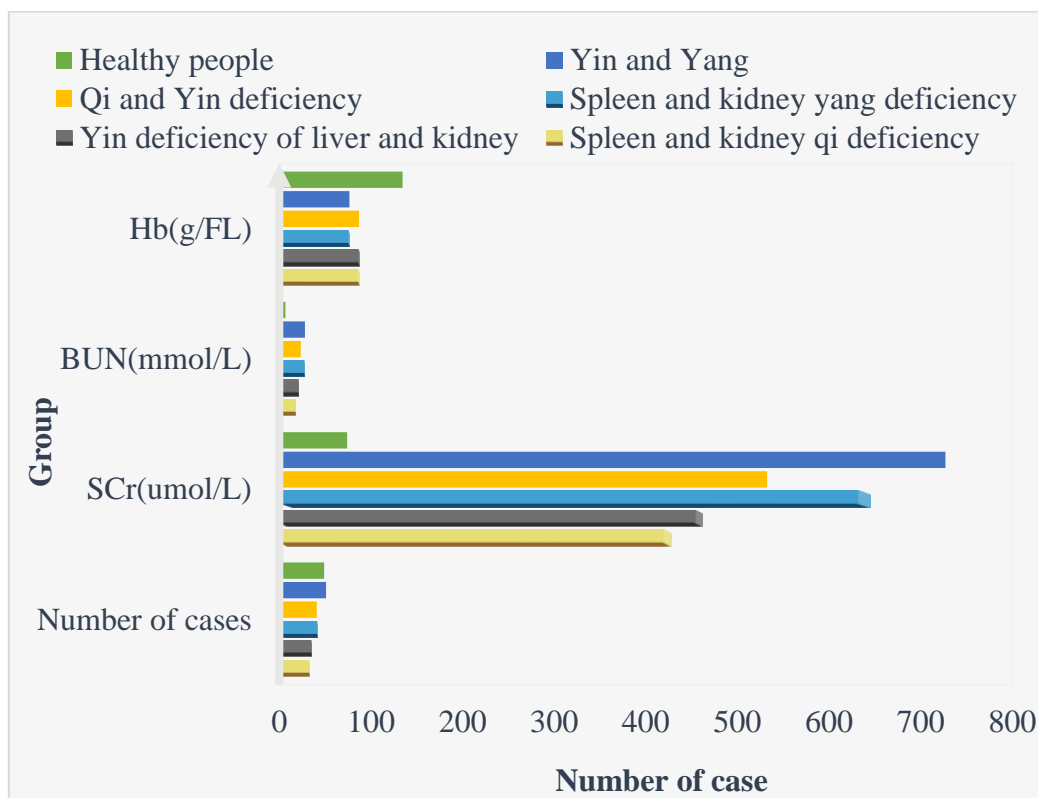


Figure 4. Results of lung function tests in each group

As shown in Figure 4, the lung function index also showed a downward trend with the increase

of blood creatinine and urea nitrogen, and there was a significant negative correlation between the two. Chronic renal failure in the uremic stage is the common fate of the progress of various kidney diseases to the end stage. The accumulation of multiple metabolites caused by this disease can cause damage to multiple systems and organs throughout the body. The lung is one of the organs most commonly affected by uremia. Uremic lung, also known as uremic pulmonary edema and uremic pneumonia, is a non-infectious and characteristic interstitial pulmonary edema with an incidence of up to 60%. The clinical symptoms of uremic lung are relatively mild and disproportionate to X-ray performance. Pulmonary function is mainly restricted ventilation dysfunction, partly manifested as mixed ventilation dysfunction, and lung diffusion function is introduced, but many indicators of lung function in CRF patients do not necessarily change only during the uremic stage. Some scholars found that Even if there are no obvious symptoms and signs, CRF patients have mechanical ventilation and hemodynamic changes, mainly manifested as: reduced vital capacity, mild restrictive ventilation disorder; decreased carbon dioxide diffusion capacity: correction of anemia after carbon dioxide diffusion capacity and blood urea Nitrogen was negatively correlated and positively correlated with creatinine clearance. The detection rate of pulmonary dysfunction in patients with chronic renal failure was significantly higher than the abnormal chest radiographs during the same period. This means that the parameters of lung function detection have certain sensitivity. In addition, patients with chronic renal failure are susceptible to external pathogenic factors due to low immunity, and they have bronchitis, bronchopneumonia, interstitial pneumonia, and pleural effusion. In particular, lung infection is the most important manifestation of uremic respiratory system. The problem is one of the main causes of death of CRF patients. Lung involvement can be clinically detected by lung function tests. Traditional lung function indicators such as vital capacity and one second volume are related to the patient's age, height, weight, gender and other factors. Their absolute values are often not good in different populations. For comparison, the comparison with the predicted value is now used to reflect the change in lung function, and the change in lung function is more accurately reflected than in the past.

## 5. Conclusion

In this study, it is believed that internal fistula-associated bacteremia is associated with aneurysm resection. Bleeding is related to the surgical method. Heart failure is related to the surgical site and blood flow of internal fistula. Therefore, in order to improve the success rate of internal fistula and reduce the occurrence of complications, it is necessary to formulate a reasonable preoperative risk evaluation system based on the above factors. Adequate preoperative preparation, reasonable surgical site, skilled surgical skills and scientific postoperative management are also key.

The establishment of an effective vascular access is the most fundamental prerequisite for hemodialysis and the lifeline of hemodialysis patients. The artificial blood vessel internal fistula solves the difficult problem of internal fistula occlusion or the establishment of autologous arteriovenous internal fistula, and greatly improves the quality of life of hemodialysis patients. As the success rate of artificial vascular fistula surgery increases, this vascular path will be more widely used in clinic. Preventing the complications of artificial blood vessel fistula and prolonging the life span of artificial blood vessel fistula is the focus of nursing work.

Arteriovenous fistula is the lifeline of hemodialysis patients, and its longevity and functional status directly affect the quality of dialysis treatment, survival and quality of life of patients. The combination of far infrared irradiation and external application of fresh potato chips can effectively treat the hematoma, swelling and pain of arteriovenous fistula. The combination of the two can achieve synergistic and synergistic effects, so that the subcutaneous hematoma and swelling of the arteriovenous fistula quickly subside and restore the arteriovenous Internal fistula function, reduce

late complications such as arteriovenous fistula stenosis, improve blood flow and patency rate of arteriovenous fistula, prolong its service life, and improve the quality of life of patients. This method is a non-invasive, safe, simple, and economical nursing intervention method. The equipment materials are simple and the popularity is strong. From the research observations in this article, it is shown that this method has various major complications related to arteriovenous fistula puncture. It has definite and reliable curative effect, is economical and practical, and is worthy of clinical promotion.

### Funding

This article is not supported by any foundation.

### Data Availability

Data sharing is not applicable to this article as no new data were created or analysed in this study.

### Conflict of Interest

The author states that this article has no conflict of interest.

### References

- [1] Kang L , Grande J P , Hillestad M L , et al. (2016). "A New Model of an Arteriovenous Fistula in Chronic Kidney Disease in the Mouse: Beneficial Effects of Upregulated Heme Oxygenase-1", *Am J Physiol Renal Physiol*, 310(6),pp.F466.<https://doi.org/10.1152/ajprenal.00288.2015>
- [2] Almási-Sperling, Veronika, Galiano M , Lang W , et al.(2016). "Timing of First Arteriovenous Fistula Cannulation in Children on Hemodialysis", *Pediatric Nephrology*,31(10):1-11.<https://doi.org/10.1007/s00467-016-3382-9>
- [3] Lee K G , Chong T T , Goh N , et al. (2017). "Outcomes of Arteriovenous Fistula (AVF) Creation, Effect of Preoperative Vein Mapping and Predictors of Fistula Success in Incident Hemodialysis Patients - A Single-center Experience", *Nephrology*, 22(5),pp.382-387.<https://doi.org/10.1111/nep.12788>
- [4] Evans A , Gazaille R E , Mckenzie R , et al.(2017). "Acquired Uterine Arteriovenous Fistula Following Dilatation and Curettage: an Uncommon Cause of Vaginal Bleeding", *Radiology Case Reports*, 12( 2),pp.287.<https://doi.org/10.1016/j.radcr.2017.01.005>
- [5] Shiu Y T , Litovsky S H , Cheung A K , et al. (2016). "Preoperative Vascular Medial Fibrosis and Arteriovenous Fistula Development",*Clinical Journal of the American Society of Nephrology*,11(9),pp.1615-1623.<https://doi.org/10.2215/CJN.00500116>
- [6] Vajihe A , Masoumeh B N , Nouraddine M S , et al. (2016). "Comparison of the Effects of Hegu Point Ice Massage and 2% Lidocaine Gel on Arteriovenous Fistula Puncture-Related Pain in Hemodialysis Patients: A Randomized Controlled Trial", *J Caring*, 6(2), pp.141-151.<https://doi.org/10.15171/jcs.2017.014>
- [7] Cho S . (2017). "The Feasibility of Surgical Salvage of Thrombosed Arteriovenous Fistula by an Interventional Nephrologist", *Kidney Research & Clinical Practice*, 36(2),pp.175-181.<https://doi.org/10.23876/j.krcp.2017.36.2.175>
- [8] Fontser é N ástor, Mestres G , Yugueros X , et al. (2016). "Effect of a Postoperative Exercise Program on Arteriovenous Fistula Maturation: A Randomized Controlled Trial", *Hemodialysis*

- International International Symposium on Home Hemodialysis*, 20(2),pp.306-314.<https://doi.org/10.1111/hdi.12376>
- [9] Mudoni A , Caccetta F , Caroppo M , et al. (2016). “Echo Color Doppler Ultrasound: a Valuable Diagnostic Tool in the Assessment of Arteriovenous Fistula in Hemodialysis Patients”, *Journal of Vascular Access*, 17(5),pp.446.<https://doi.org/10.5301/jva.5000588>
- [10] Nagpal P , Bathla G , Saboo S S , et al.(2016). “Giant Idiopathic Renal Arteriovenous Fistula Managed by Coils and Amplatzer Device: Case Report and Literature Review”, *World Journal of Clinical Cases*,4(11),pp.364-368.<https://doi.org/10.12998/wjcc.v4.i11.364>
- [11] Ragupathi L , Johnson D , Marhefka G D . (2016). “Right Ventricular Enlargement within Months of Arteriovenous Fistula Creation in 2 Hemodialysis Patients”, *Tex Heart Inst J*, 43(4),pp.350-353.<https://doi.org/10.14503/THIJ-15-5353>
- [12] Eric C , Velazquez C C , Fabrizio D , et al. Arteriovenous fistula construction with the VasQ external support device: a pilot study, *The journal of vascular access*, 17(3),pp.243.<https://doi.org/10.5301/jva.5000527>
- [13] Narechania S , Tonelli A R . (2016) .“Hemodynamic Consequences of a Surgical Arteriovenous Fistula”, *Annals of the American Thoracic Society*, 13(2),pp.288.<https://doi.org/10.1513/AnnalsATS.201509-636CC>
- [14] Aurshina A , Ascher E , Hingorani A , et al.(2018). “A Novel Technique for Duplex-Guided office-Based Interventions for Patients with Acute Arteriovenous Fistula Occlusion”, *Journal of Vascular Surgery*, 67(3),pp.857.<https://doi.org/10.1016/j.jvs.2017.07.135>